

RAPID HEALING OF A PAINFUL VENOUS LEG ULCER USING SUB-SENSORY MICROCURRENT ELECTRICAL STIMULATION: A CASE STUDY

Authors: Clare Holland [1], Liz Ovens [2]

Affiliations: [1] Leg Ulcer Specialist Nurse, HertsOne leg Ulcer Service, Central London Community Health NHS Trust ; [2] Independent Tissue Viability Specialist Nurse, UK

Introduction

Many patients living with a chronic non-healing wound suffer with pain, reduced mobility, and increased risk of infection, sepsis, amputation and death [1-4]. Electrical stimulation therapy (EST) is an advanced wound therapy which can reduce wound pain and stimulate healing [4]. There is low awareness amongst clinicians of the use of sub-sensory EST in patients with venous leg ulcers (VLUs), especially for patients when severe pain is causing intolerance to gold standard compression therapy. The aim of this case study was to explore the effects of a sub-sensory EST device* on pain relief and wound healing for a patient with a painful, non-healing VLU who had limited tolerance to standard wound care.

Method

A wearable, single use, sub-sensory EST device* (see figure 1) was applied alongside standard care including therapeutic compression therapy for a single patient for the recommended 12-day treatment period. Wound dimensions and wound pain (visual analogue score [VAS, 0= no pain-10= worst pain]) were monitored. Informed consent was obtained prior to application of the EST device*.

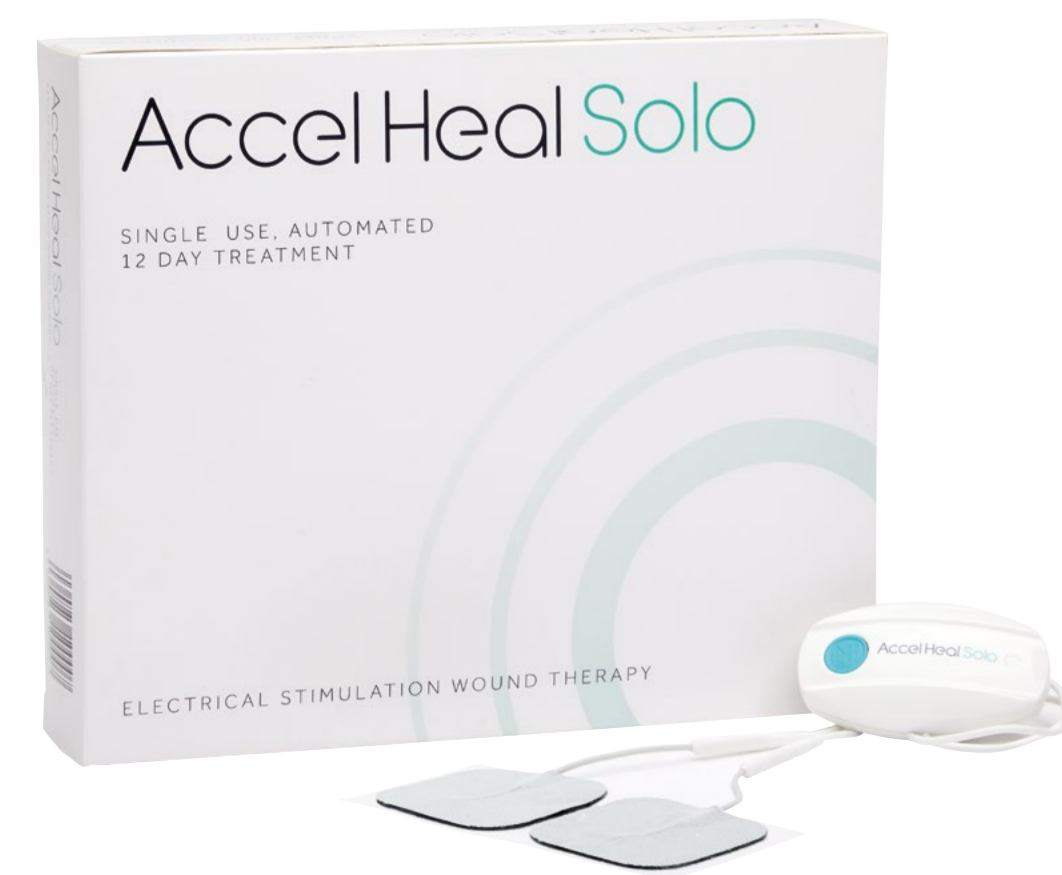

Figure 1. Accel-Heal Solo

Case study:

A 77 year old male, presented to the community leg ulcer clinic with a painful, non-healing VLU, present for 15 weeks, to his right medial malleolus. The patient's past medical history included hyper-cholesterolaemia, hypertension, left inguinal hernia repair and relatively recent right total hip replacement. The patient was usually very active and had been hoping that his normal activities could resume following his hip replacement, however the high level of wound-related pain was limiting his mobility and impacting his sleeping. He also found dressing changes very difficult due to the pain and found compression therapy uncomfortable. He was taking paracetamol to help with the wound-related pain but was intolerant to stronger analgesia, which caused abdominal discomfort.

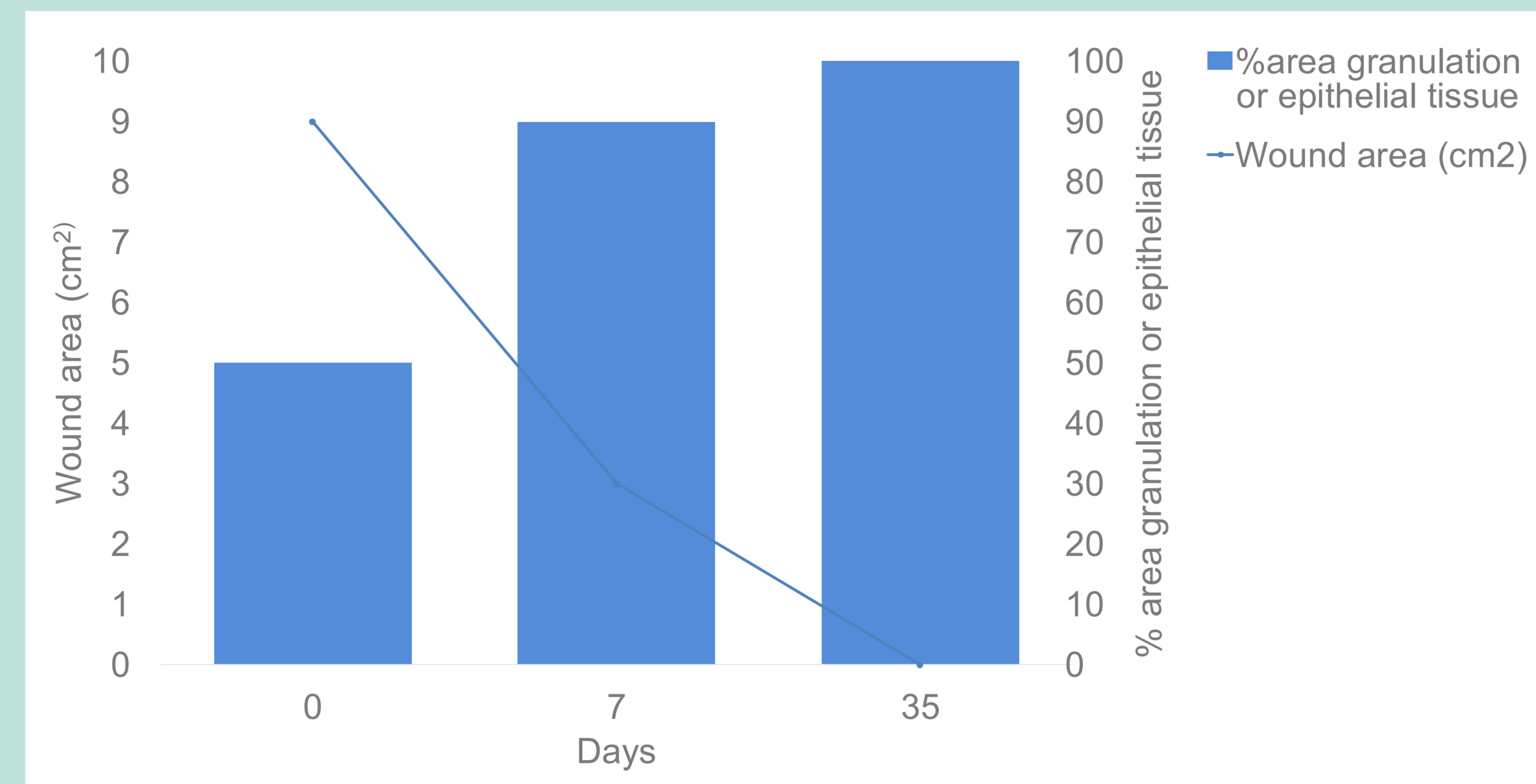


Figure 2. Changes in wound characteristics in one patient

Changes to wound area and the % area of the wound composed of granulation or epithelial tissue are shown in Figure 2. The change in wound pain following initiation with EST* is shown in Figure 3.

Prior to EST* the VLU measured 9 cm² with 50% slough and 50% granulation tissue (Figure 4). Wound-related pain scored 6 (VAS), worsening at night, and complicating cleansing and debriding.

By day 7 after the initiation of Accel-Heal Solo, the wound had reduced from 9 cm² to 3 cm² (67% reduction, Figure 5), with 90% granulation. Wound pain decreased from 6 to 5 (VAS). By day 35, the wound was fully healed and pain was 1 (VAS) (Figure 6). The patient reported that his sleeping had improved and he was walking again.

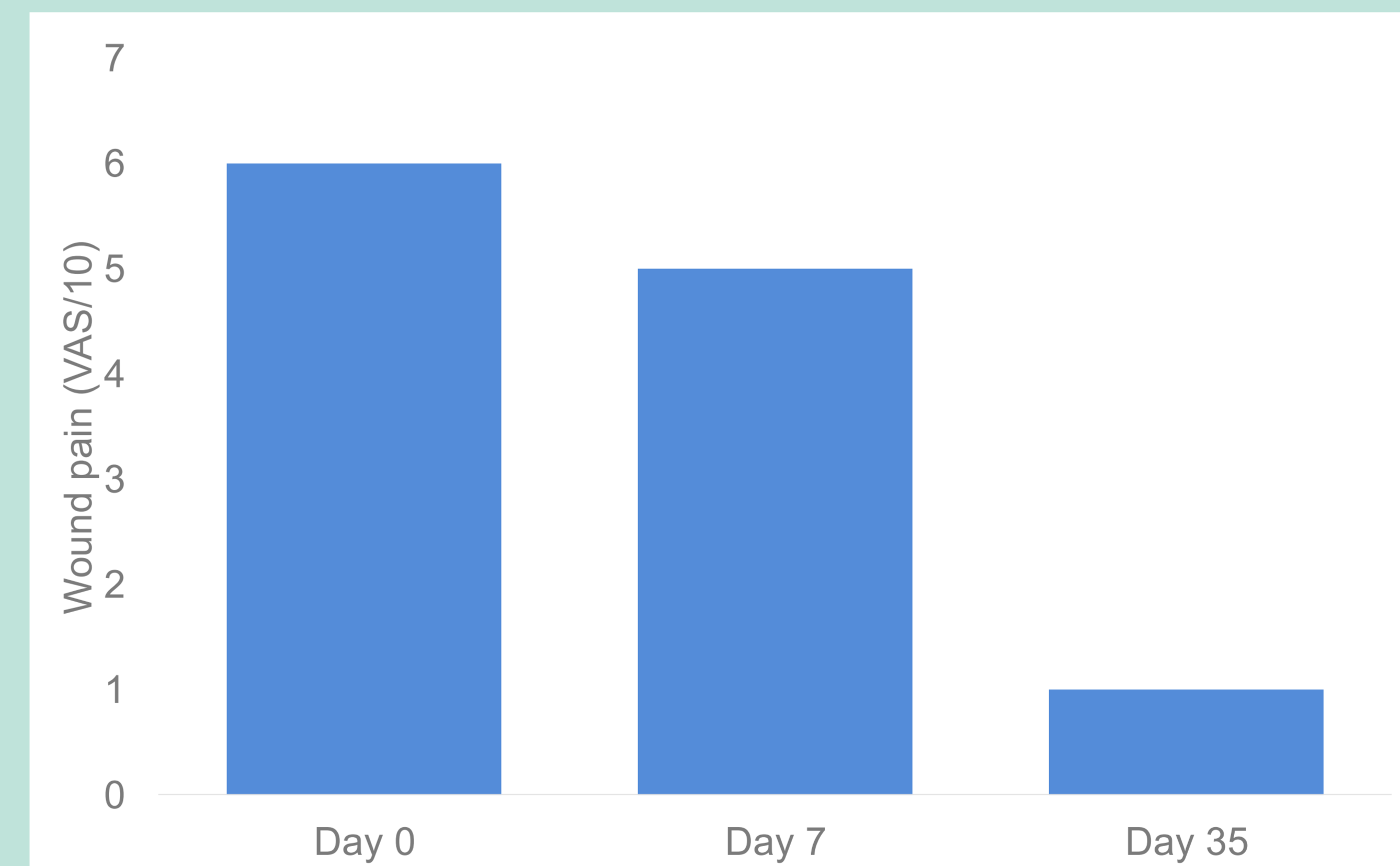


Figure 3. Changes in wound pain in one patient

Discussion and Conclusion:

EST stimulates cellular activity in the wound bed, enhancing endogenous healing processes. In this patient, relief from wound-related pain improved his quality of life (sleep, mobility) and tolerance of standard wound care (including cleansing, debridement and compression), cumulatively supporting rapid healing. In this case, 12 days of sub-sensory EST was associated with rapid healing of a painful VLU, improved pain control, and enhanced patient quality of life. The clinical team described the effect as transformative for this patient, and the patient was "absolutely delighted" that his ulcer had healed.

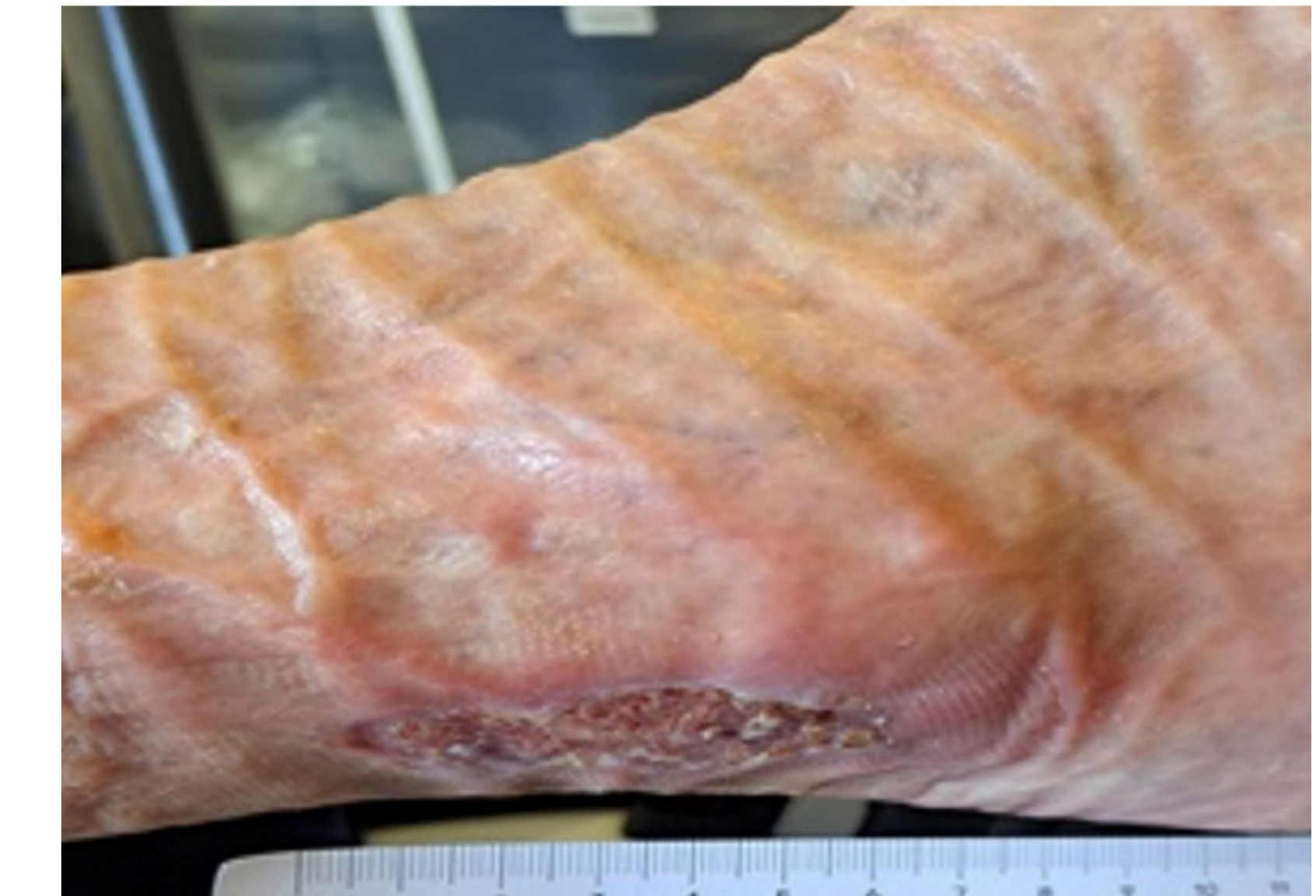

Figure 4. Day 0

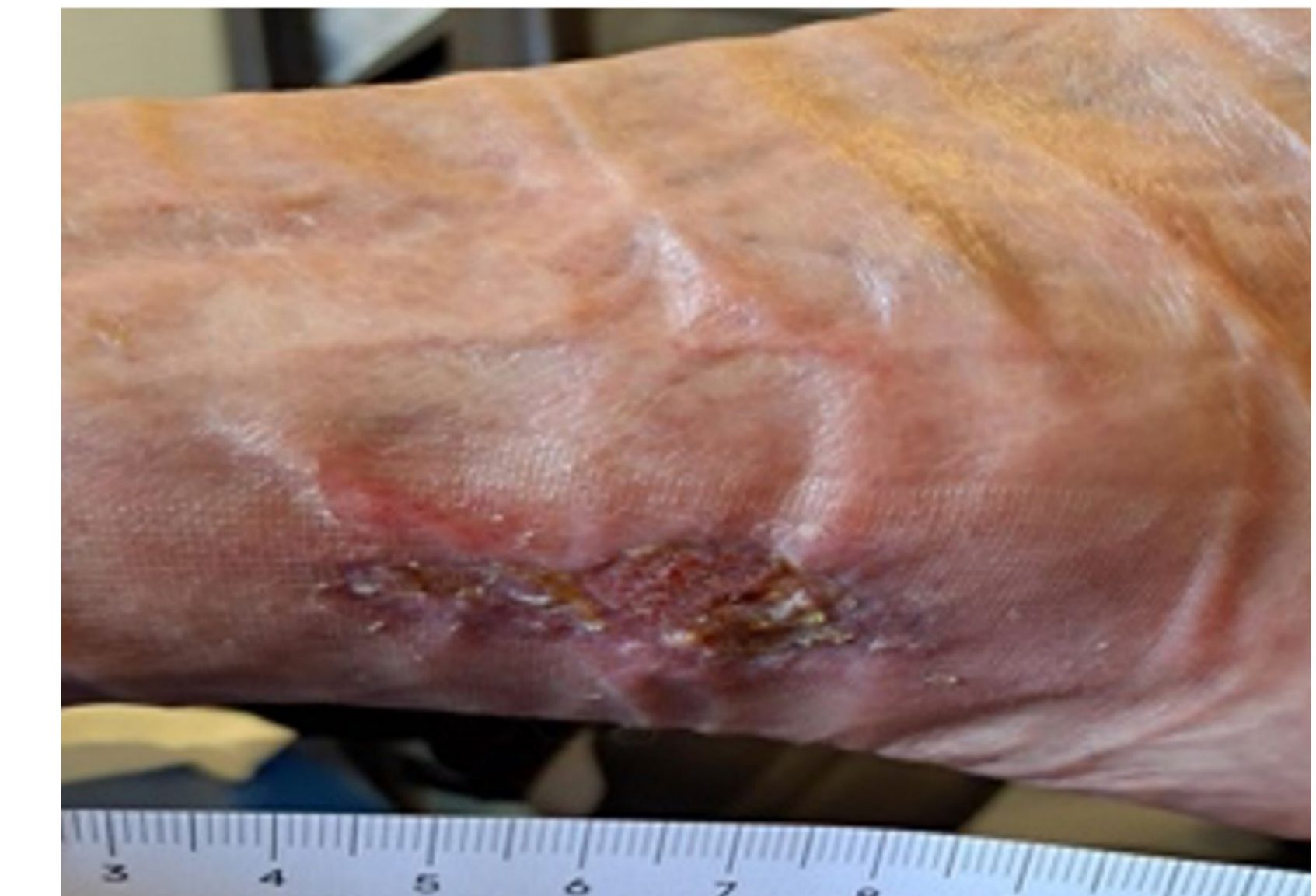

Figure 5. Day 7

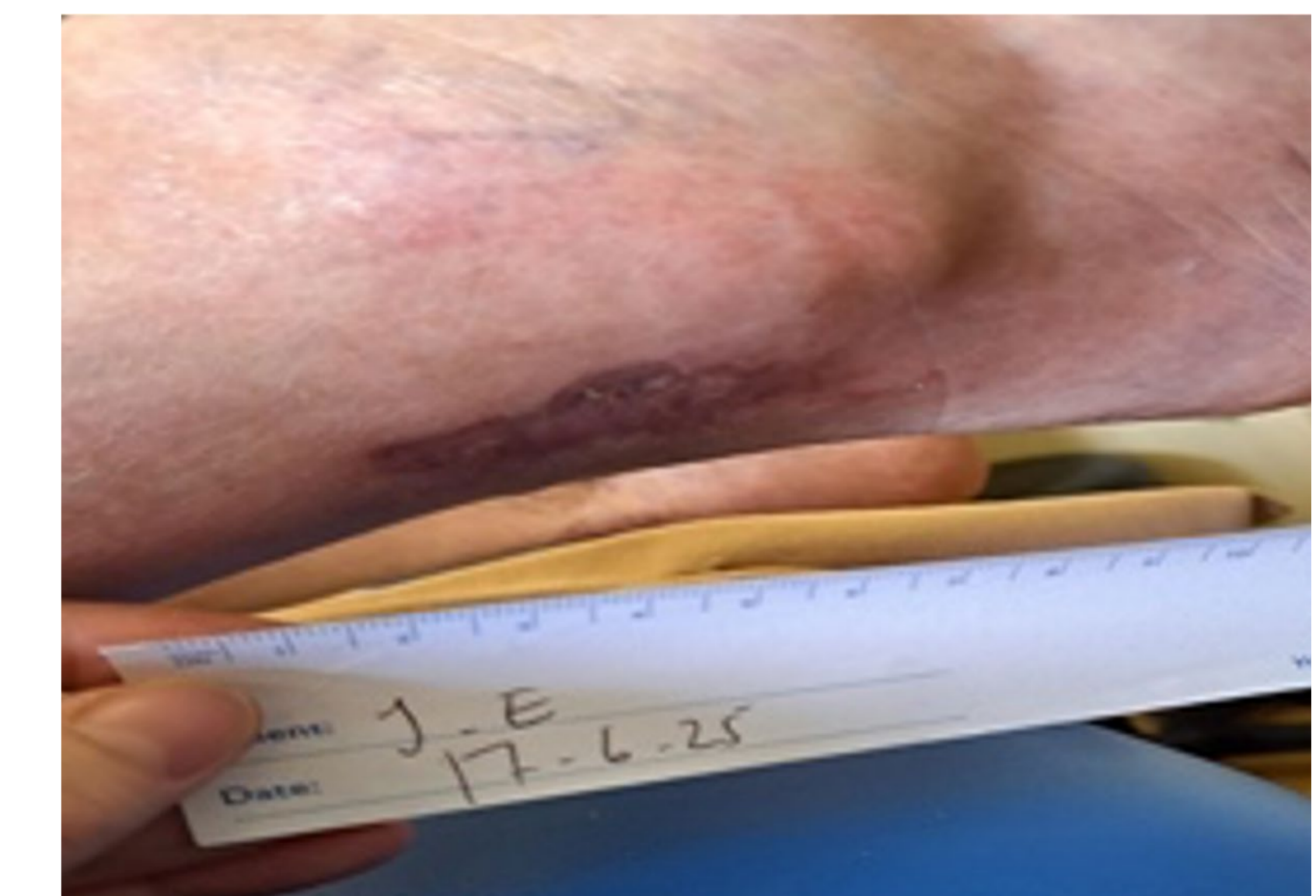

Figure 6. Day 35

Abbreviations: EST, electrical stimulation therapy; VAS, visual analogue score; VLU, venous leg ulcer. | **Disclosures:** Writing services were paid for by Accel-Heal Technologies Limited but were carried out independently.

References: 1. González-Consuegra RV, Verdú J (2011) J Adv Nurs 67(5): 926-44; 2.Hopman W., Vandenberghe E., Carly M et al (2016). International Wound Infection Institute (IWII) (2022). Wound Infection in Clinical Practice. Wounds International; 3.Smith J., Carville K., Maguire K et al (2023). Wound Practice & Research: Journal of the Australian Wound Management Association. 2023; 31(4):164-173; 4. Milne J, Swift A, Smith J, Martin R. J Wound Care. 2021 Jul 2;30(7):568-580.

*Accel-Heal Solo, Accel-Heal Technologies Limited, Hever, Kent, UK. Presented at Wounds UK, Harrogate, 2025.