

# Stimulation of healing and reduction in wound-related pain following treatment with a microcurrent EST device\* in a community setting

Jane Hampton,<sup>1</sup> Winnie Knop Schjøtt,<sup>1</sup> Mette Gorell Riis.<sup>1</sup>

1. Consultant Nurse (Wound Management), Aarhus Kommune, Aarhus, Denmark.

## Introduction:

Electrical stimulation therapy (EST) can be applied to hard-to-heal wounds to stimulate the healing process and reduce pain. The aim of this study was, to assess the ability of a wearable, easy to use microcurrent EST-device\* to stimulate healing and reduce wound-related pain in a series of hard-to-heal wounds, being treated by community nurses.

## Methods:

- Single-centre prospective observational study conducted in Denmark
- Changes in wound area were monitored for 4 weeks prior to application of EST.\* Only patients with static or deteriorating wounds were enrolled.
- The microcurrent EST device\* was applied for 12-days (except in one patient who received a second application of microcurrent EST)^ along-side appropriate standard wound dressings, in line with the label.
- Wound area was measured at the onset of treatment with microcurrent EST (baseline) and every two weeks thereafter until healing, or up to 24 weeks.
- Wound pain was measured per patient using the 0-10 visual analogue scale (VAS) at baseline and after 7-days of EST\*.

## Results:

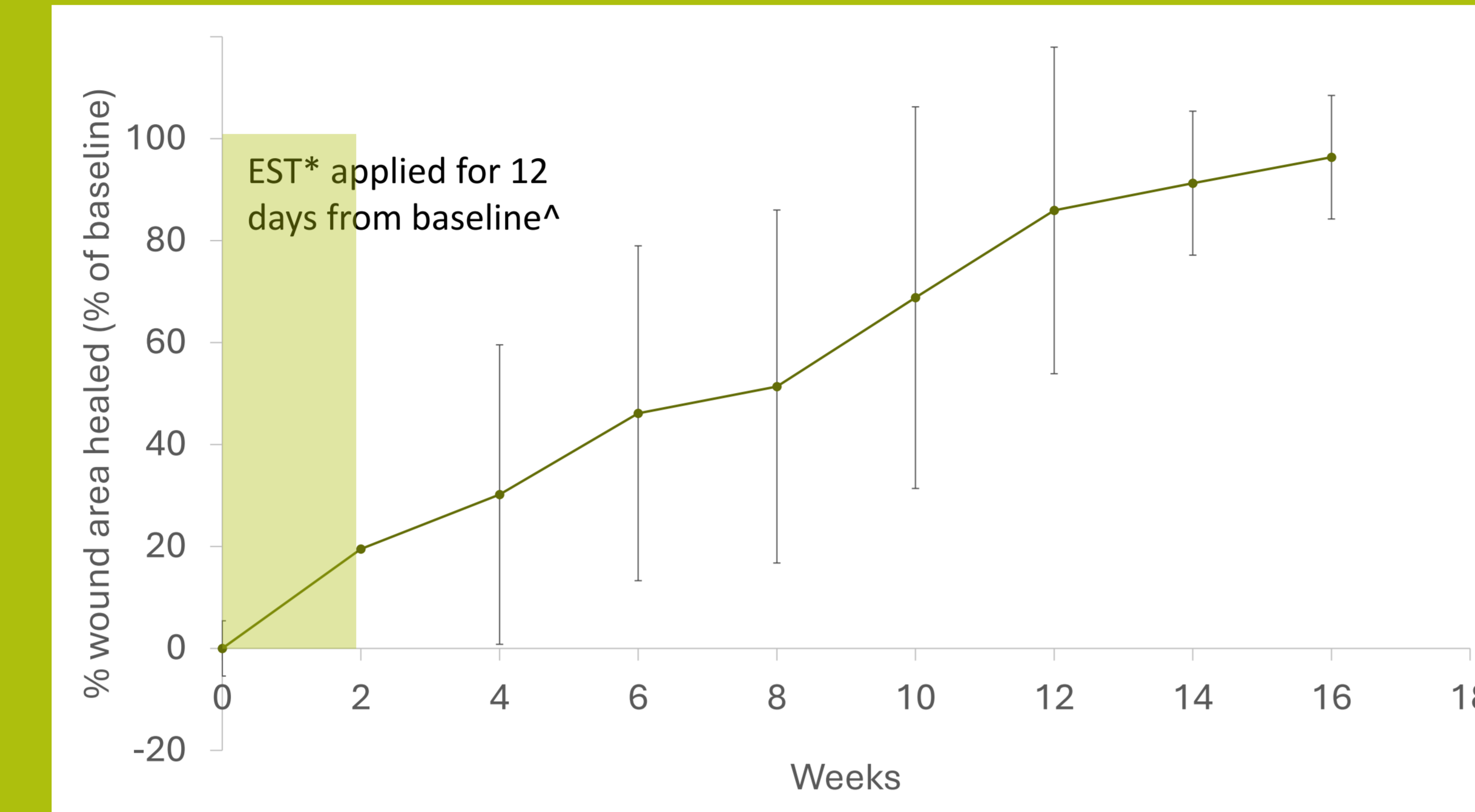
- 20 patients with 22 wounds were included in the analysis.
- Demographic and wound characteristics, are shown in **Table 1**.

		Enrolled patients (n=20)
Demographics	Female, n (%)	13 (65)
	Mean age, years (range)	76.6 (50-96)
		Enrolled wounds (n=22)
Wound status, n(%)	Static	11 (50)
	Deteriorating	7 (31.8)
	Minimal improvement	1 (4.5)
	Unknown	3 (13.6)
Wound size	Median (IQR) change in wound area in 4 weeks prior to EST,* %	0 (-2.6 – 0)
	Median (IQR) baseline area, cm <sup>2</sup>	4.5cm <sup>2</sup> (1.8-7.5)
Wound aetiology	Venous ulcer	5 (22.7)
	Pressure ulcer	6 (27.3)
	Arterial ulcer	3 (13.6)
	Diabetic foot ulcer	2 (9.1)
	Other	2 (9.1)
	Wound duration	Median months (IQR)

**Table 1.** Demographic and wound characteristics.

## Effect of microcurrent EST\* on healing-related outcomes

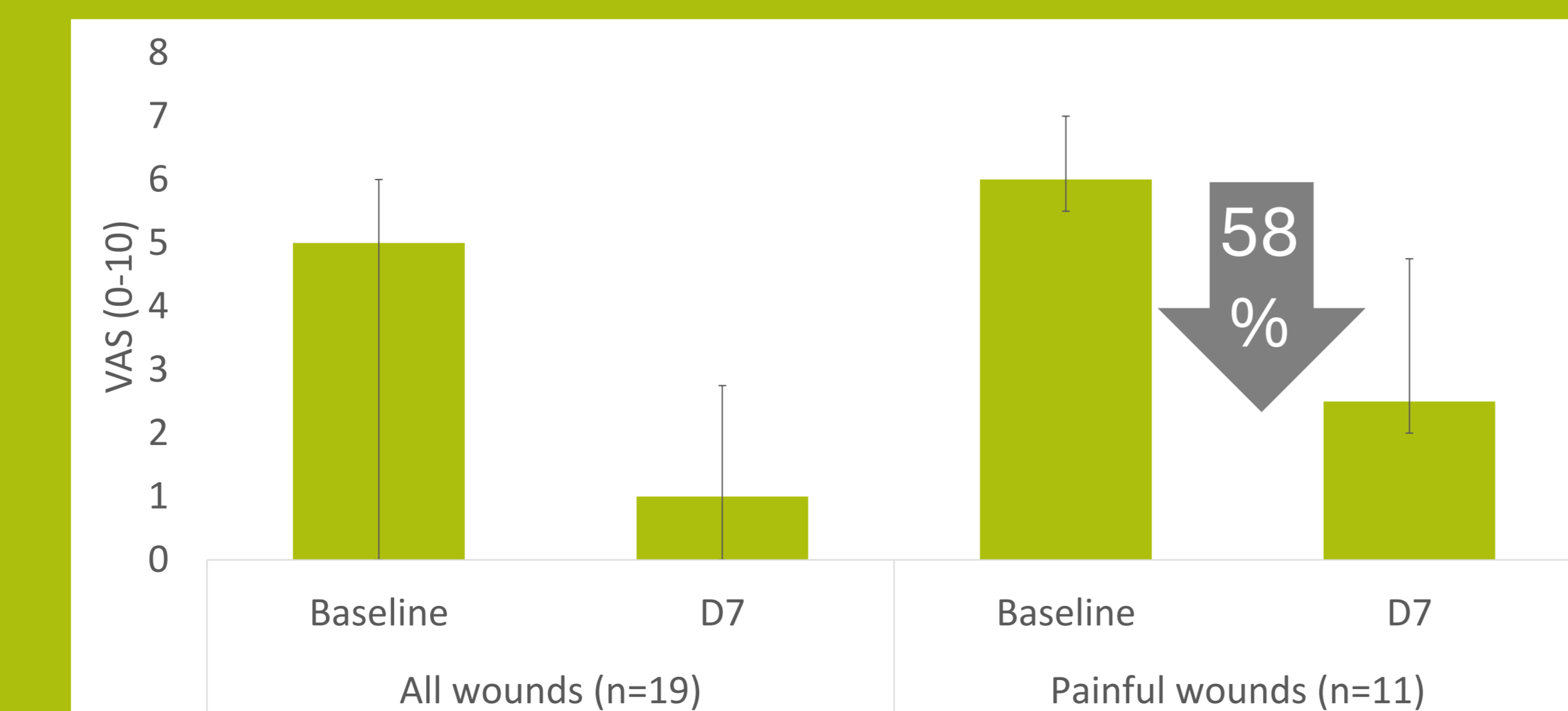
- Eight weeks after the start of treatment, mean wound area had reduced by 51.4% (SD 37.4, n=21 wounds). This increased to 85.9% (14.1, n=13) and 96.4% (6.8, n=11) reduction after 12 and 16 weeks, respectively.
- Overall, 11/22 wounds healed within a median of 15.7 weeks (IQR 7.5-18.5).



**Figure 1.** Effect of microcurrent EST on wound healing. Showing % healing by wound area, compared with baseline area (arrow, representing 0% healed), n=22 wounds in 20 patients.

## Effect of microcurrent EST\* on wound pain

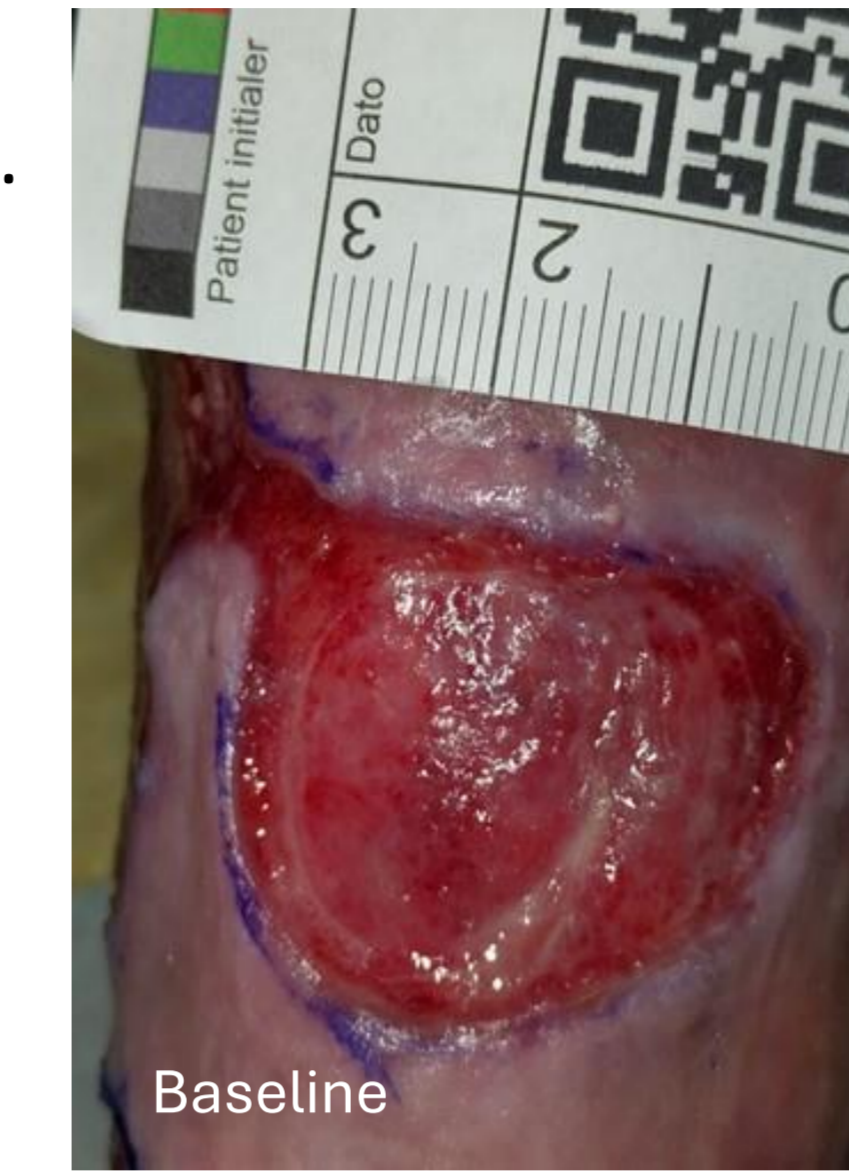- Wound pain was recorded in 19/20 patients. At baseline, eleven (55%) patients had moderate or severe wound pain (VAS ≥4), two (10%) reported mild wound pain (VAS 1-≤4) and six patients (30%) had pain-free wounds.
- Across all 19 patients, within 7 days of treatment with Accel-Heal, wound pain reduced from a median VAS of 5.0 (IQR 0.0-6.0) to VAS 1.0 (IQR 0.0-7.8)
- In the eleven patients with moderate to severe wound pain at baseline, pain reduced from a median of 6.0 (IQR, 5.5-7.0) to 2.5 (IQR 2.0-4.8), representing a median reduction of 58% (IQR, 43.3-72.9%)



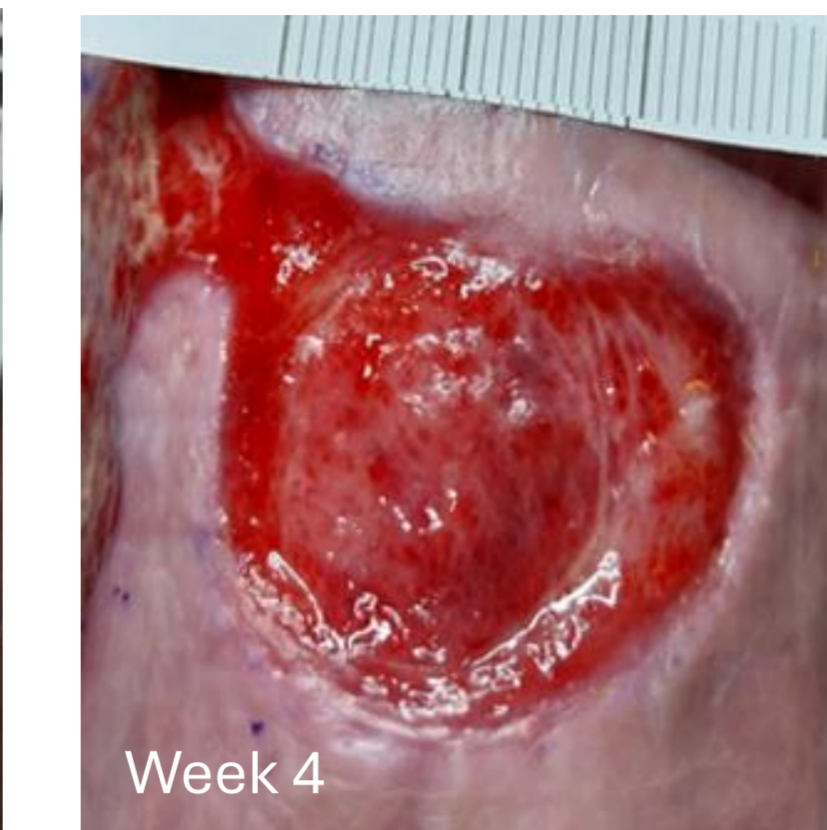
**Figure 2.** Effect of microcurrent EST on wound pain. Pain reported per patient n=19.

## Case 1

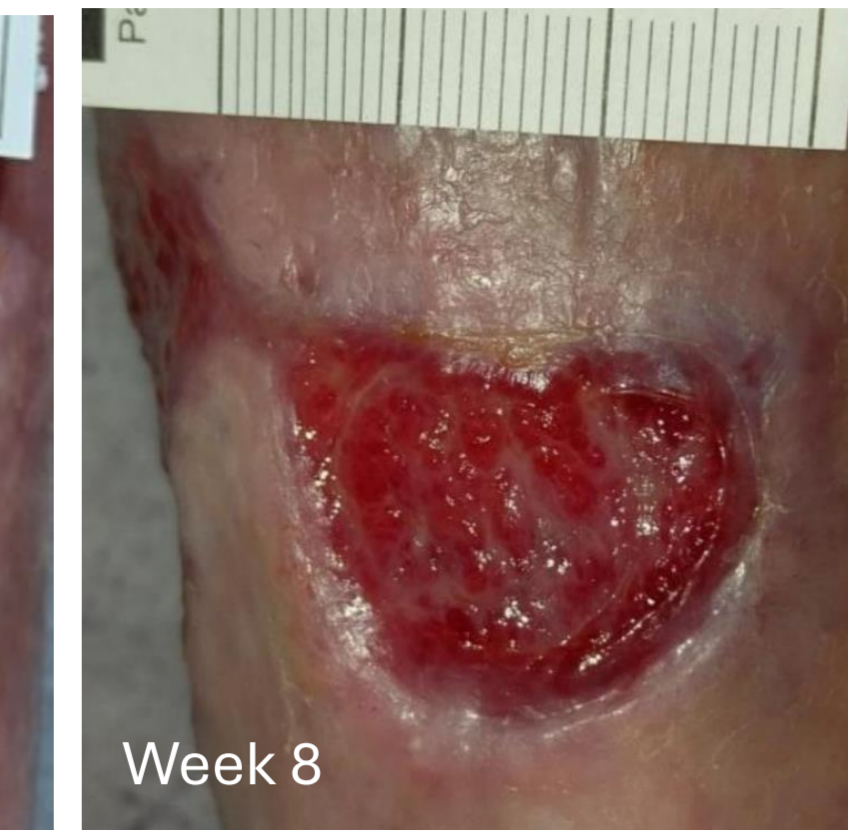- 87-year-old woman.
- Painful mixed leg ulcer with pyroderm granulorum
- Duration of 15 months
- Treated with morphine gel, hydrofiber and Coban Lite
- Minimal change in the wound in prior 4 weeks



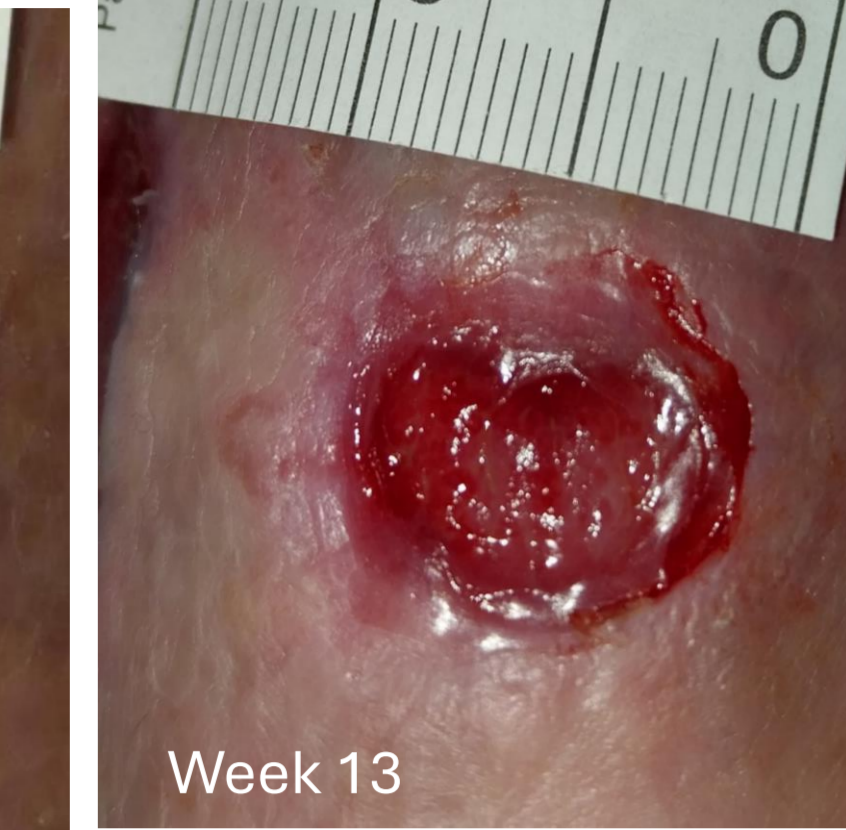- Treated with Accel-Heal for 24 days
- **Day 7:** Wound pain had reduced from 9/10 to 5/10



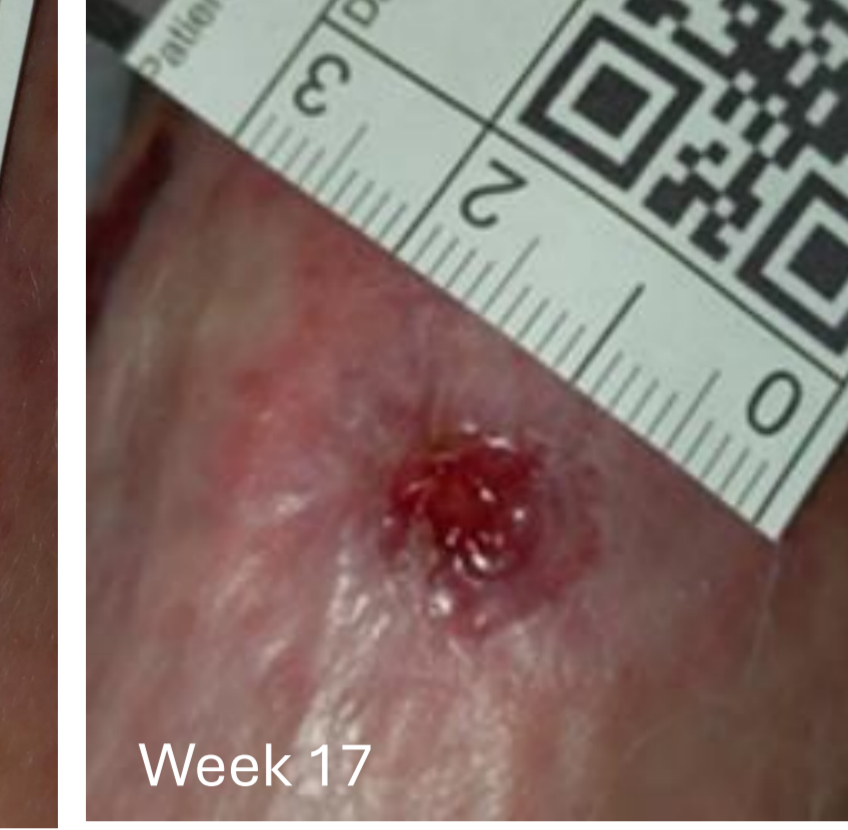- **Week 4:** Wound pain reduced further to 2/10



- **Week 6:** wound was 33% smaller vs baseline
- **Week 8:** wound was 54% smaller



- **Week 13:** Wound size was reduced by 65% vs baseline

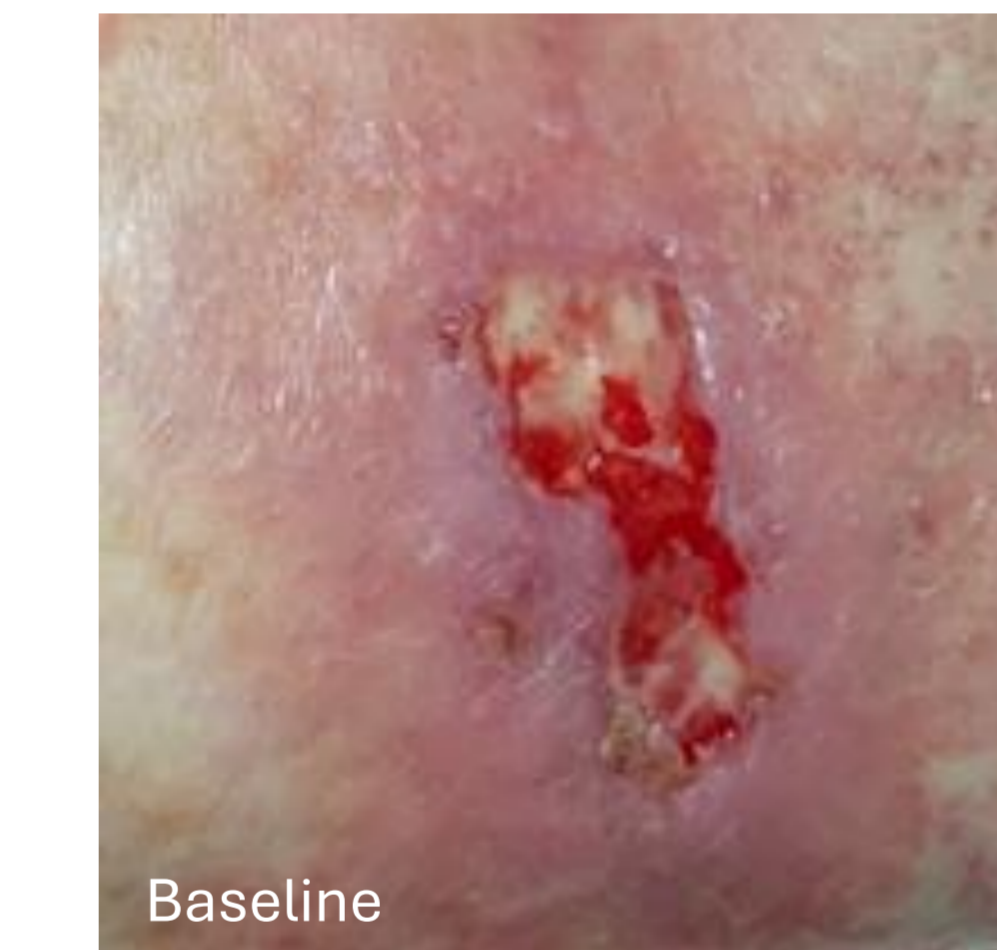

- **Week 17:** Only very small wound remained

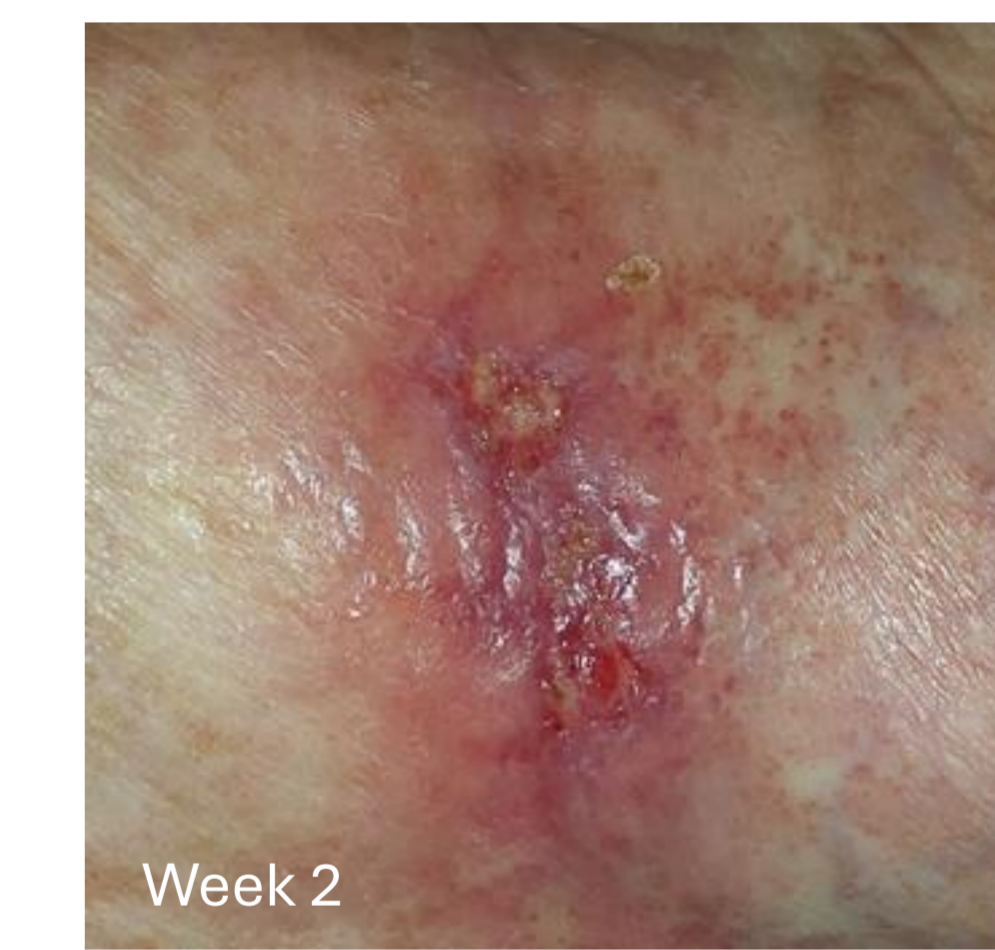Healed at 18 weeks

## Case 2

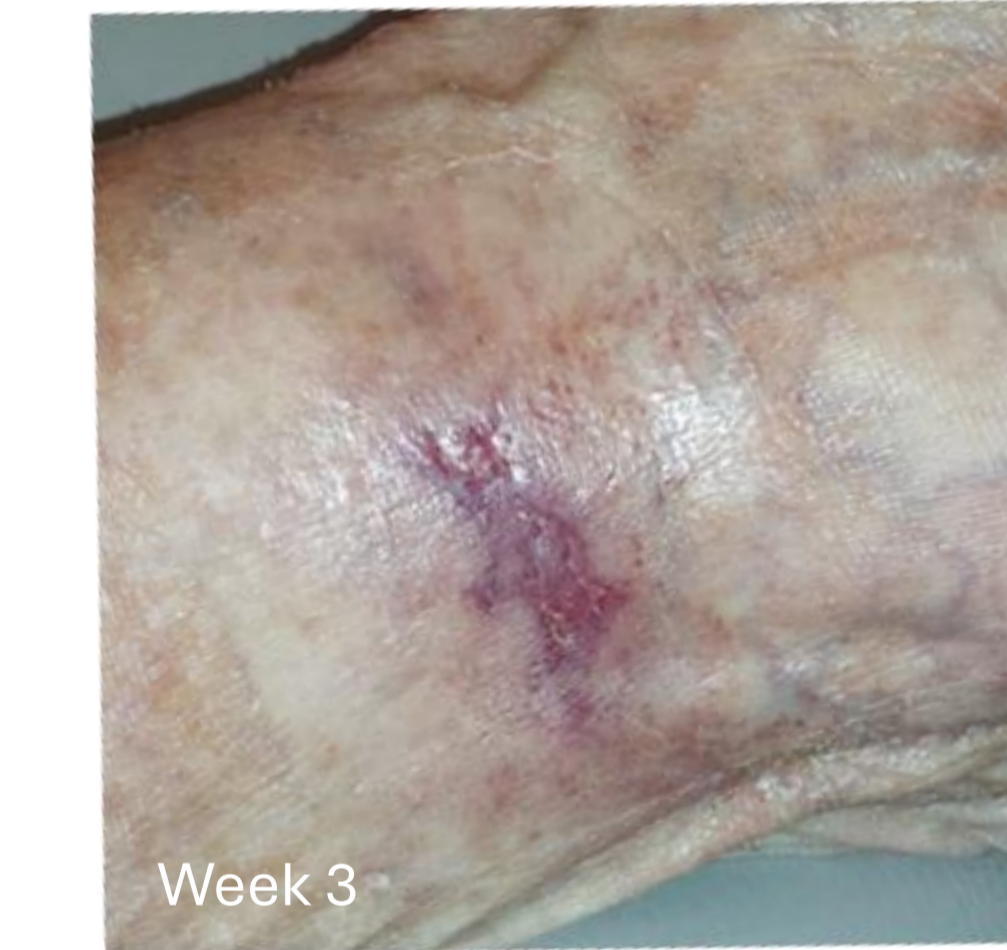- 83 year old woman.
- Venous leg ulcer
- Duration of 7 months
- Wound area 1.5cm<sup>2</sup>
- Not able to wear compression due to pain in foot and leg
- Neuropathic pain of unknown cause; VAS score of 6
- Rheumatoid arthritis, asthma, COPD
- Slight deterioration of the wound in the 4-week run-in period, despite twice weekly treatment with hydrocolloid and tubifast



- Treated with Accel-Heal for 12 days
- **Day 2:** VAS score reduced from 6/10 to 2/10.
- **Day 3:** Patient said there is no need to talk about pain because there isn't really any.
- **Day 5:** Patient decided to start using a class 1 compression stocking



- **Week 2:** After 12 days with Accel-Heal, wound was 80% smaller



- **Week 3:** Only very small wound area (0.05 cm<sup>2</sup>) remained

Healed at 4 weeks

## Discussion:

- The wounds enrolled in this study had been present for a long duration prior to treatment and all had failed to respond to treatment in the four weeks prior to application of the microcurrent EST device.
- Reductions in wound-related pain observed in the first 7-days of treatment were clinically meaningful in the majority of patients who reported wound pain.
- The wound area reduction represented an improvement in condition compared to the lack of progress / deterioration, that had been seen prior to application of EST.
- The study is on-going and aims to treat a further 40 patients.

## Conclusion:

Microcurrent EST had a rapid and positive impact on wound-related pain and stimulated many previously static or deteriorating wounds onto a healing trajectory.

\*Accel-Heal Solo, Accel-Heal Technologies Limited, Hever, Kent, UK.

^One patient received a second application of microcurrent EST