

# CASE STUDIES

Using innovative Accel-Heal electrical stimulation therapy in the treatment of hard-to-heal wounds

## HARD-TO-HEAL WOUNDS CONTINUE TO BE A MAJOR BURDEN

Despite therapy advances in wound management over the last 30 years, hard-to-heal wounds are an increasing problem.

The total cost of leg ulcers in the UK has been estimated to be around £1.9bn each year. <sup>[1]</sup>

The annual cost of managing an unhealed venous leg ulcer (VLU) is 4.5 times more than that of managing a healed one. <sup>[2]</sup>

The majority of patients require dressing changes at least twice a week and more than a third require daily dressing changes, putting pressure on health care practitioner caseloads. <sup>[3]</sup>

Hard-to-heal wounds can be extremely painful - between 50% and 60% of patients with chronic wounds experience persistent wound pain. <sup>[4, 5]</sup>

Pain influences many aspects of wound therapy. One major issue is that pain can make some gold standard therapies such as compression unbearable; this can lead to reduced compliance and worse outcomes. Wound pain can also severely impact patients' quality of life.

## WHAT IS ELECTRICAL STIMULATION

Electrical stimulation has the potential to alleviate these problems. It is a proven therapy method for wound management which has been used by specialists and researchers for many years.

It is one of the most evidence-based wound management technologies available, reported in at least 30 randomised controlled trials. <sup>[6, 7]</sup> Its use has been recommended by the European Pressure Ulcer Advisory Panel to treat stage 2 to 4 pressure ulcers. <sup>[8]</sup>

The European Wound Management Association (EWMA) has also acknowledged that electrical stimulation is effective in treating a wide range of wound types including venous leg ulcers, diabetic foot ulcers, pressure ulcers and mixed ulcers. <sup>[9]</sup>

Electrical stimulation is proven to improve healing <sup>[6,9]</sup> whilst reducing pain <sup>[10, 11]</sup> and inflammation <sup>[12]</sup>. Specific subsensory stimulation from devices such as Accel-Heal<sup>®</sup> is safe to use. <sup>[9]</sup>

However, electrical stimulation has not been widely adopted into everyday practice. Many established, hospital-based devices are complicated for healthcare practitioners to use. Patients are inconvenienced by the need to visit the hospital for therapy and would rather be treated at home. <sup>[9]</sup>



## HOW ACCEL-HEAL ADDRESSES THESE PROBLEMS

Accel-Heal is an innovative electrical stimulation therapy for hard-to-heal wounds which relieves pain and stimulates healing.

Accel-Heal has been designed to provide advanced therapy in a simple format that can be used to complement standard wound care.

A single use, small, portable device that can be discreetly tucked away and can easily be managed by patients in their own homes.

There is no complicated set up and therapy is started with the simple push of a button. The therapy is subsensory and safe to use.<sup>[7]</sup>

## HOW ACCEL-HEAL IMPROVES OUTCOMES



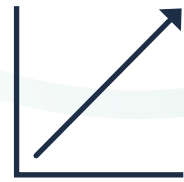
**RELIEVES WOUND PAIN**

[13][7]



**STIMULATES HEALING**

[13-15]



**IMPROVES PATIENT QUALITY OF LIFE**

[14-16]



**SAFE**

[7]



**COST EFFECTIVE**

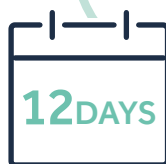[7]

## THE EVIDENCE

During Accel-Heal therapy patients can expect to find that pain is relieved and the normal healing process is stimulated and

continues long after the therapy period has been completed, putting them on the road to recovery.

**83%**



**83 per cent reduction in pain during 12-day therapy**<sup>[13]</sup>

**>80%**



**Over 80 per cent of non-healing wounds healed in 20 weeks**<sup>[13-15]</sup>

## HOW ACCEL-HEAL BENEFITS PATIENTS

### **Better quality of life**

- ⦿ Patients have reported marked pain relief following therapy with Accel-Heal<sup>[7,13]</sup> with some patients reporting rapid improvement within hours of commencing therapy.<sup>[17]</sup>
- ⦿ This has enabled patients to reduce, or come off pain relieving medication completely<sup>[18,19]</sup> and even return to work.<sup>[19]</sup>
- ⦿ Patients were also able to return to normal social activities thanks to experiencing less pain and increased mobility.<sup>[14,18]</sup>

### **Better compliance to gold standard compression**

- ⦿ Patients treated with Accel-Heal were able to tolerate full strength compression as a direct result of its pain relieving benefits.<sup>[19,20]</sup>

- ⦿ Accel-Heal can also be used to manage patient pain in order to allow investigations such as blood flow testing or other therapies such as debridement to be carried out which the patient might not otherwise be able to tolerate.<sup>[17]</sup>
- ⦿ Being entrusted with their Accel-Heal device promotes a sense of self-sufficiency and control in patients and may help to prepare them for their future self-care with, for example, compression stockings.<sup>[21]</sup>

### **Better movement and exercise**

- ⦿ Improved blood flow, stimulated by movement, can improve the chances of wound healing - as wound pain can worsen during movement, this can be very difficult for patients.
- ⦿ Patients treated with Accel-Heal noted huge differences in their ability to move about freely compared with the restrictions they had experienced before therapy, making it easier to exercise.<sup>[14,18]</sup>

## ACCEL-HEAL IS COST SAVING

Accel-Heal reduces the overall cost of hard-to-heal wound therapy by:

# £936

REDUCING THE PER  
PATIENT COST OF  
MANAGING A VLU BY  
UP TO £936  
<sup>[27]</sup>

# 1/3

REDUCING THE  
COSTS OF DRESSING  
CHANGES BY UP  
TO A THIRD  
<sup>[22]</sup>

# 34%

REDUCING THE  
NUMBER OF  
NURSING VISITS  
NEEDED PER PATIENT  
PER YEAR BY 17, A  
34% REDUCTION<sup>[23]</sup>

# 11%

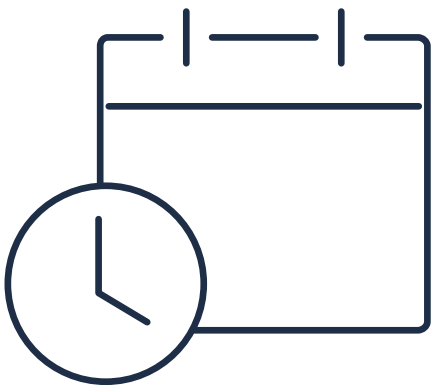
REDUCING THE COST  
OF THERAPY OF  
VENOUS LEG ULCERS  
TO THE NHS  
BY 11%<sup>[23]</sup>

## HOW ACCEL-HEAL WORKS

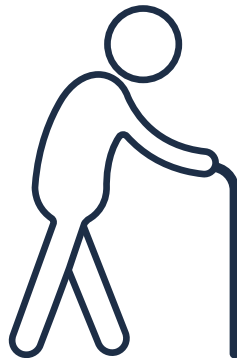Accel-Heal works by delivering a preset, automated programme of subsensory electrical pulses to the wound that automatically adjusts itself to different patients to deliver effective therapy from the moment it is switched on. A normal wound usually has a small, naturally occurring electric charge across it. This charge normally orchestrates the complicated wound healing process by instructing cells in the wound bed to go into 'healing mode'.<sup>[24]</sup>

Chronic wounds are believed to lack this electrical charge - applying electrical stimulation is believed to replicate this natural stimulation, promoting healing.<sup>[10]</sup> Accel-Heal relieves pain and stimulates healing by directly affecting cell behaviour in and around the wound bed. These cellular changes suggest that Accel-Heal may dampen down the inflammatory environment that is present in complex wounds. Case studies have reported a visually apparent reduction in wound inflammation in as little as 7-days after applying the Accel-Heal device.<sup>[14]</sup>


## HOW ACCEL-HEAL IMPROVES OUTCOMES



**Patients with a hard-to-heal wound that is not progressing to healing**



**Patients who are frustrated by the reduced mobility caused by their pain**



**Patients whose wound pain causes them to be non-compliant to therapy**



## CASE STUDY ONE

## REDUCING PAIN, ALLOWING COMPRESSION THERAPY

### SUMMARY

A patient with a venous leg ulcer could not tolerate any compression therapy because of pain scoring 10/10.

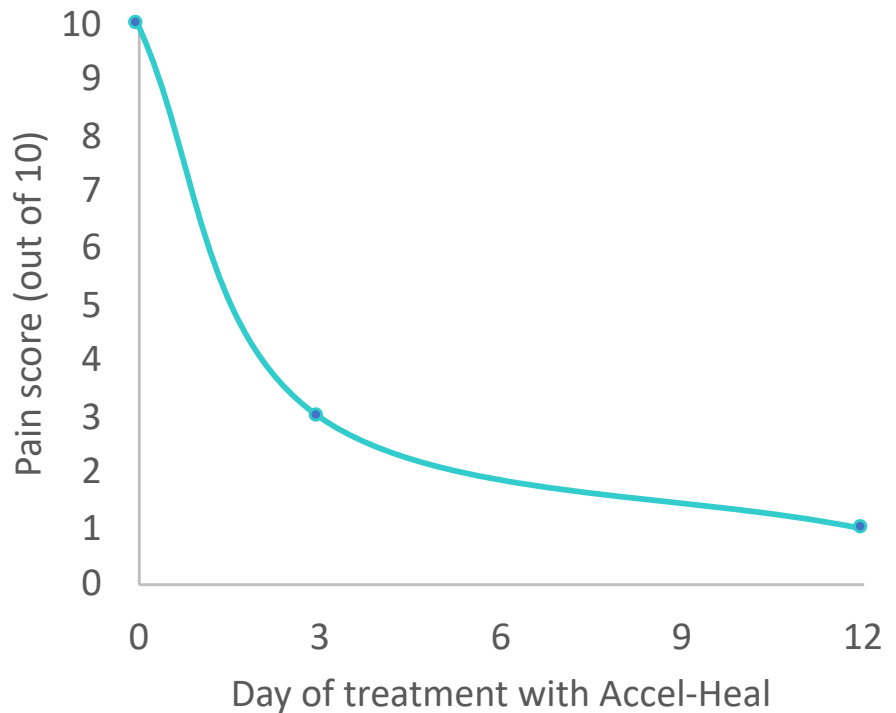
Therapy with Accel-Heal rapidly relieved the pain, allowing graduated compression therapy to be started. The wound healed three weeks after starting Accel-Heal therapy.

### BEFORE ACCEL-HEAL

A 50-year-old patient with a history of recurring venous leg ulcers despite wearing compression hosiery, presented with a very painful ulcer of three-weeks duration. The patient had previously suffered from fracture of the right ankle. Limb assessment confirmed advanced venous disease. The patient's wound was excruciatingly painful with a pain score of 10/10 despite taking co-codamol and pregabalin.

The wound pain caused her to cry with the discomfort, particularly during dressing changes. Various topical cleansers, honey and absorbent dressings with support bandages had been applied. She had also had several courses of antibiotics.

Although graduated compression therapy was considered, the patient could not tolerate the therapy because of the wound pain. She also could not tolerate the assessment of ankle-brachial pressure index (ABPI), although all foot pulses were audible with tri-phasic and bi-phasic sounds.



**AFTER 3 DAYS**  
**PAIN SCORE REDUCED TO 1/10 FROM 10/10**

## DURING THERAPY

Accel-Heal was started in December 2016 - the aim was to relieve the pain sufficiently to measure ABPI and to enable the patient to wear graduated high compression bandaging. At the beginning of therapy, the wound measured approximately 7.5cm<sup>2</sup>.

Along-side Accel-Heal, the wound was dressed with a topical honey dressing and highly absorbent secondary dressing and a support bandage. The peri-wound skin was protected with barrier cream. During dressing changes the wound was irrigated with anti-microbial irrigation fluid.

Three days after starting Accel-Heal therapy, the patient returned to clinic for a scheduled dressing change. Her pain score was much reduced to 3/10. She reported sleeping better and was now able to tolerate dressing changes.

The pain continued to improve during therapy. The wound itself also significantly improved with a reduction in wound size and exudate. At the end of the 12-day therapy the pain was minimal and only small dry scabs remained.

## AFTER ACCEL-HEAL

At the end of the 12-day Accel-Heal therapy, graduated short stretch compression bandaging was applied. The aim was to continue short stretch bandaging until good tensile strength was obtained in the wound and then to measure for compression hosiery to prevent recurrence. The wound was completely healed, and the patient was discharged with compression hosiery in February, around two months after Accel-Heal therapy.

The patient was so grateful for the 'wonderful result' and in particular she expressed the delight in achieving a 'normal and pain free Christmas', which she had been very worried about. She was surprised by the speed of recovery and more importantly the reduction in pain being so significant within a few days of therapy.

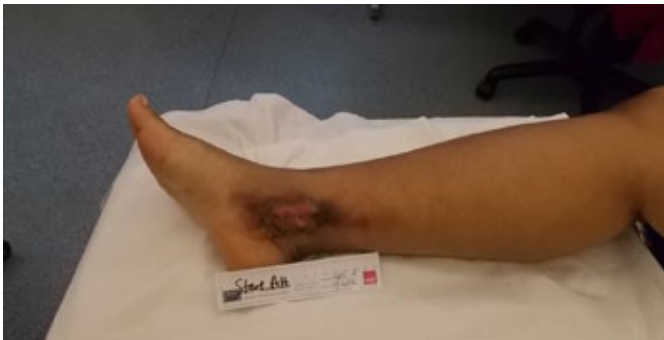

Figure 1. Wound to right medial malleolus on 15/12/16

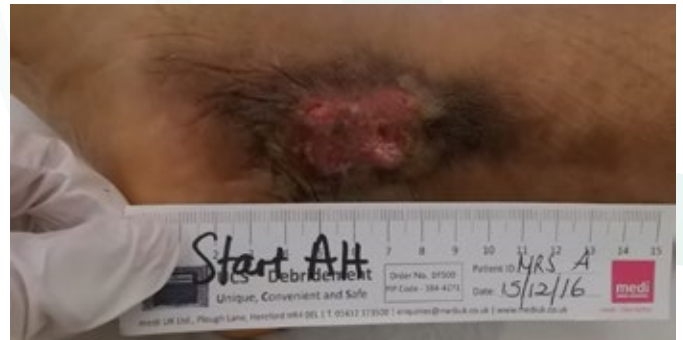

Figure 2. Wound to right medial malleolus on 15/12/16

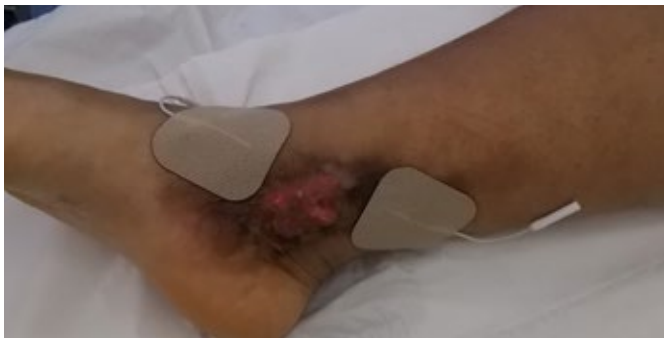

Figure 3. Commencing Accel-Heal on 15/12/16

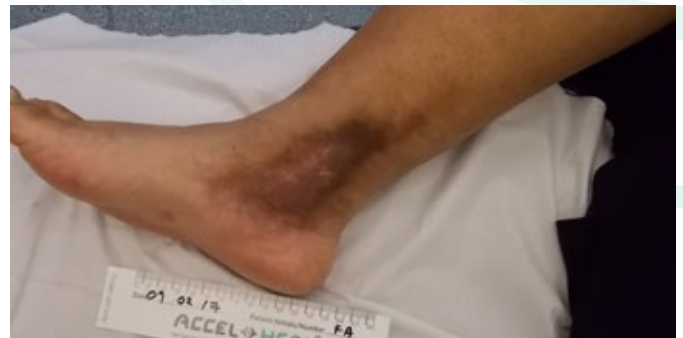

Figure 4. Right medial malleolus on 09/02/17. Wound healed



## CASE STUDY TWO

## REDUCING PAIN, ALLOWING COMPRESSION THERAPY

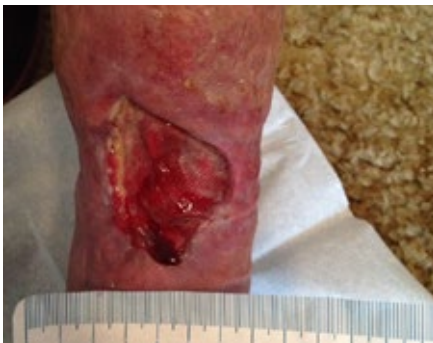### SUMMARY

90-year-old patient sustained a traumatic wound resulting in a non-healing venous leg ulcer which had been present for four to six months. The wound healed 12 weeks following Accel-Heal therapy.

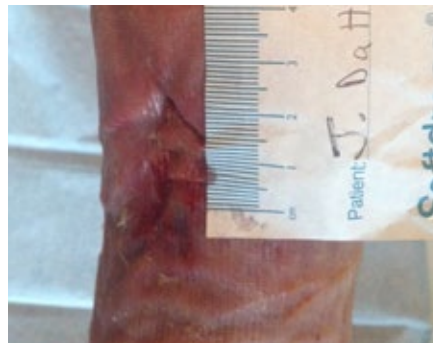### BEFORE ACCEL-HEAL

The patient had a diagnosis of dementia. Limb assessment demonstrated venous incompetence, with ankle brachial pressure index within normal limits. Compression therapy was therefore indicated but had been poorly tolerated due to her pain levels.

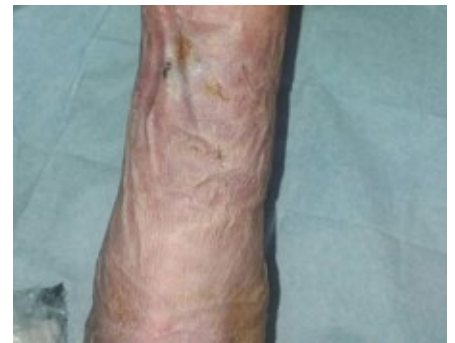The wound measured approximately 24.75 cm<sup>2</sup>. She was prescribed twice weekly dressings with honey and graduated high compression bandages. Her pain score was 5/10.



**Figure 1. Wound to left tibial crest prior to Accel-Heal on 02/11/17**



**Figure 2. Wound to left tibial crest at week 5 on 08/12/17**



**Figure 3. Wound to left tibial crest healed at week 12**



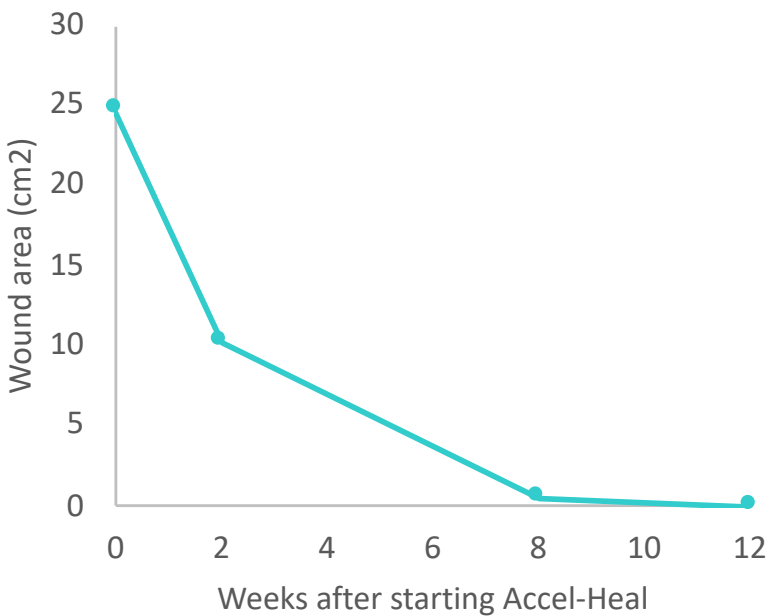
## DURING THERAPY

Therapy with Accel-Heal started in November and continued for 12 days, along-side standard care with graduated high compression therapy and primary dressings as per local protocol.

## AFTER ACCEL-HEAL

Two weeks after commencing therapy with Accel-Heal, the wound had halved in size to approximately 10.25 cm<sup>2</sup>. Exudate significantly reduced and the patient now only needed weekly dressing changes.

The wound pain score had reduced to 1/10. At week eight, the wound measured approximately 0.5 cm<sup>2</sup> with no pain and the wound had completely healed within 12 weeks.



**AFTER  
2 WEEKS**

**WOUND  
SIZE MORE  
THAN  
HALVED**

## CASE STUDY THREE

## KICK-STARTING HEALING IN A PREVIOUSLY STALLED WOUND

### SUMMARY

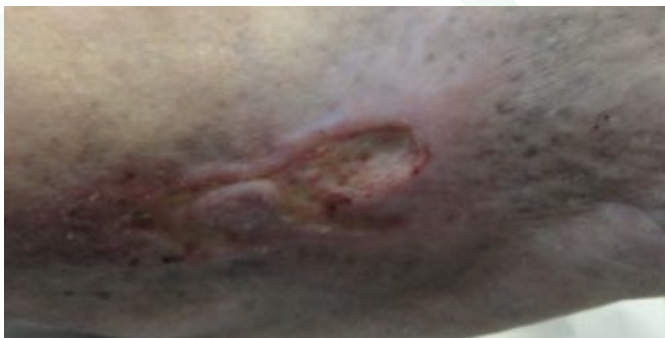A patient with recurrent arterial foot ulcers was experiencing high levels of wound pain. Therapy with Accel-Heal reduced wound pain from 8/10, to no pain, within the first 5 days of therapy.

The wound, which had been present for six months, healed nine weeks after starting Accel-Heal therapy.

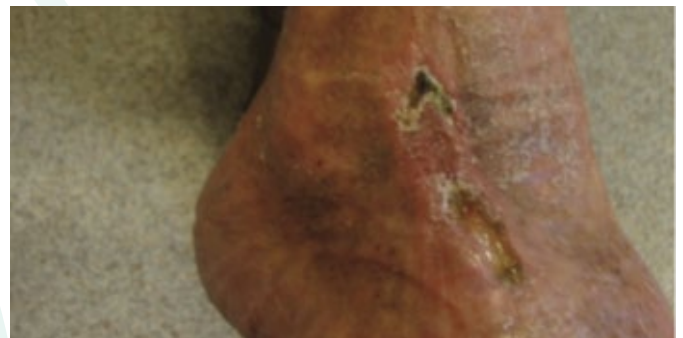### BEFORE ACCEL-HEAL

A 75-year-old patient presented with recurrent arterial foot ulcers on her right foot that had been present for four months in March 2013. She had previously experienced foot ulcers in 2009 and suffered an MRSA infection. The patient was a smoker with poor ankle movement, claw toes and poor mobility who had been self-caring for her wounds with support from her brother and husband who were podiatrists.

On presentation, there were two wounds present, measuring approximately 6cm<sup>2</sup>. The wounds were painful with a score of 8/10. A gel sheet was applied to re-hydrate the wounds. Although this initially reduced the pain to 4/10 within a few weeks (by the end of April) there were no further improvements and the pain score had increased back up to 8/10.



**Figure 1. Prior to Accel-Heal on right dorsum of foot March 2013**



**Figure 2. Right dorsum of foot 02/06/13 - 5 days after commencing Accel-Heal**

## DURING THERAPY

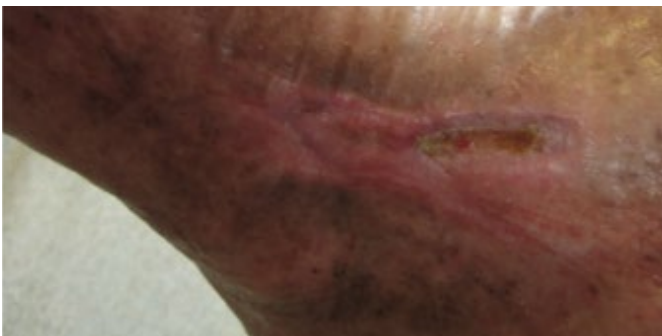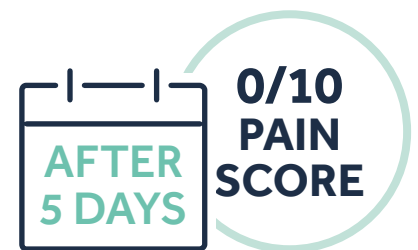Therapy with Accel-Heal began in May 2013. Accel-Heal was applied alongside the gel-sheet dressings which were changed twice weekly throughout the 12-day Accel-Heal therapy.

Within five days of commencing Accel-Heal therapy, the patient's pain score had reduced to 0/10. The wound bed was much improved, with reductions in both size and depth.

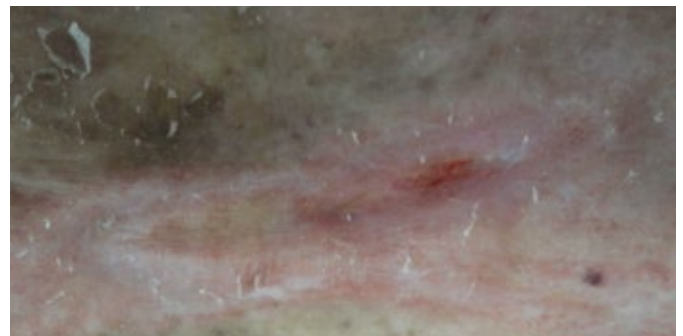## AFTER ACCEL-HEAL

After the 12-day therapy period the wound continued to be managed with gel sheet dressings, twice weekly.

The wound continued to progress and complete healing was achieved by the end of July 2013. In August 2013, the patient underwent an angioplasty to help prevent recurrence.



**Figure 3.** Right dorsum of foot 11/06/13, following completion of Accel-Heal



**Figure 4.** Right dorsum of foot 30/07/13 - Wound healed

## CASE STUDY FOUR

## KICK-STARTING HEALING IN A PREVIOUSLY STALLED WOUND

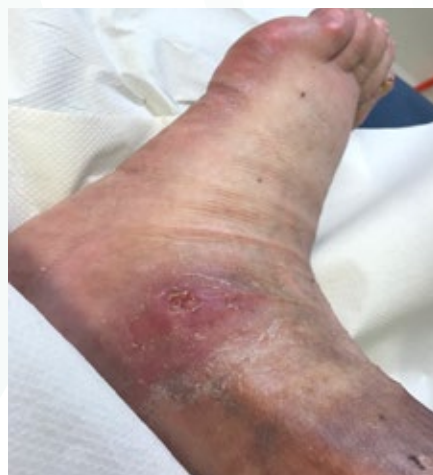### SUMMARY

A patient with a wound of 3-years duration was treated with Accel-Heal. After starting this therapy his wound healed within six weeks.

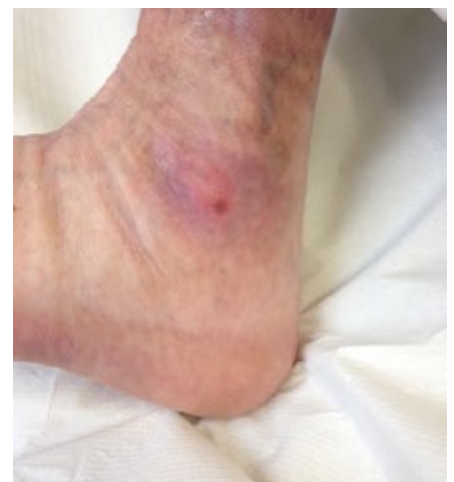### BEFORE ACCEL-HEAL

A 57-year male presented with a venous leg ulcer which had been present for three years. The patient was receiving gold standard graduated high compression bandaging but despite this, the wound had showed no signs of progress.

The patient's wound management was complicated by Type 2 diabetes, neuropathy and hypercholesteremia. Past medical history included previous vascular surgery in 2012 and 2017. The wound measured approximately 0.8cm<sup>2</sup> and 1mm deep. The wound was not painful.



**Figure 1. Wound to left lateral malleolus prior to Accel-Heal on 11/01/18**



**Figure 2. Wound to left lateral malleolus on 22/02/18 Wound healed within 6 weeks**

## DURING THERAPY

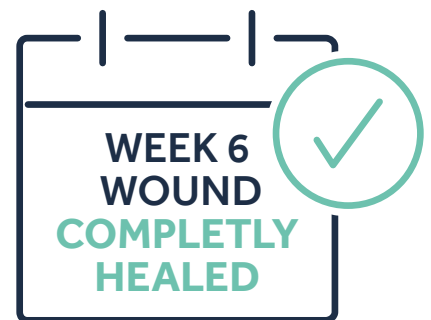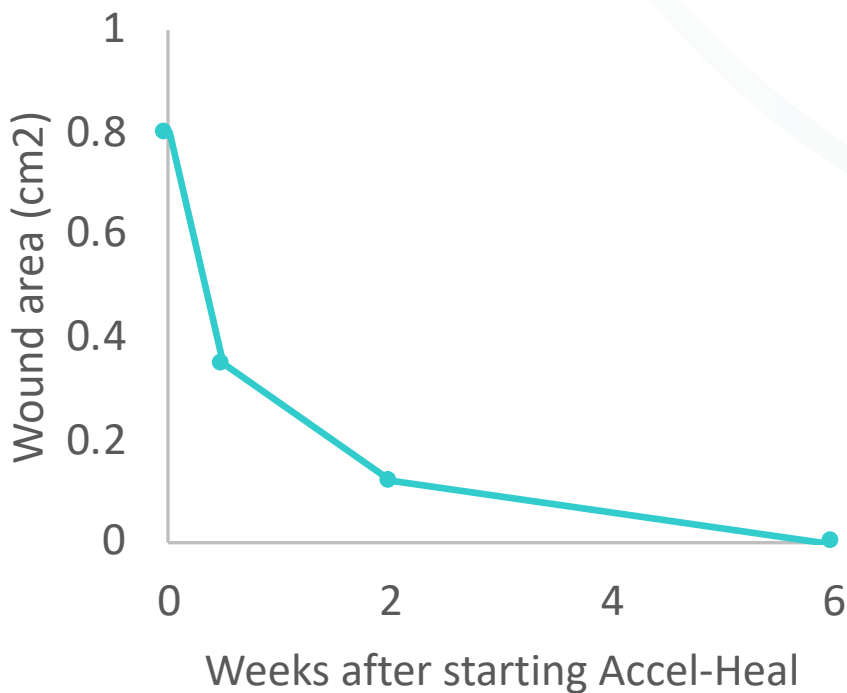
12-day Accel-Heal therapy commenced in January 2018, alongside standard moist wound management and graduated high-compression bandaging. Dressings were changed twice weekly.

The patient found the therapy very comfortable. An improvement was noted during the first dressing change, when the wound dimensions were reduced to 0.35cm<sup>2</sup> x 1mm deep.

## AFTER ACCEL-HEAL

Two weeks after commencing therapy with Accel-Heal, the wound was again reduced to only 0.12cm<sup>2</sup> with no depth. From this point, only weekly dressing changes were required.

The wound completely healed at week six and remained healed six weeks post healing. The patient was 'very happy' with the results.



## CASE STUDY FIVE

## KICK-STARTING HEALING IN A PREVIOUSLY STALLED WOUND

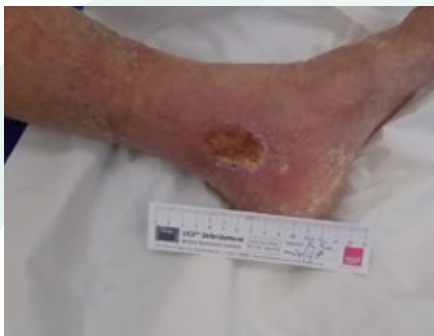### SUMMARY

A patient with bilateral recurrent venous leg ulcers, which had been present for more than four months was treated with Accel-Heal. Both wounds significantly improved within three months following Accel-Heal therapy.

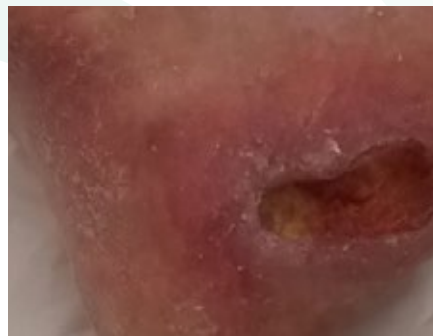### BEFORE ACCEL-HEAL

A 75-year-old patient presented with bilateral recurrent venous leg ulcers, despite wearing compression hosiery. The wounds remained unhealed at 4 months. The wound on the left leg wound measured 7cm<sup>2</sup> and the wound on the right leg wound measured 10cm<sup>2</sup>.

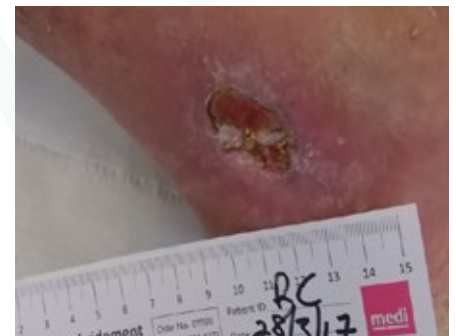Despite wearing graduated high compression bandaging for four weeks, there was no improvement noted. He was referred to the vascular team for possible vascular surgery, in view of his recurrence. His pain score was 6/10 despite taking regular co-codamol and he was referred to the GP for analgesic review.



**Figure 1. Left medial aspect 24/01/17 prior to Accel-Heal**  
accelheal.com



**Figure 2. Right medial aspect on 24/01/17 prior to Accel-Heal**



**Figure 3. Left medial wound on 28/03/17**

## DURING THERAPY

Following discussion and consent, the patient was prescribed Accel-Heal therapy with the aim of reducing wound pain and kick-start wound healing. In view of the size, depth and condition of the wound, it was decided to apply the electrode pads to the left medial wound.

Accel-Heal therapy began in February 2017 and continued for 12-days. Standard moist wound healing and graduated high-compression therapy continued during and following Accel-Heal therapy. Twice weekly dressing changes continued. The patient changed his own Accel-Heal devices every 48-hours, in line with the instructions provided.

## AFTER THERAPY

Two weeks after starting Accel-Heal therapy, there was no change to the patient's pain score, but the patient reported that much of his pain was now due to arthritis of the ankles, rather than wound-related pain. He was taking regular analgesia, following review by the GP.

By the end of March 2017, wound area on the patient's left leg had significantly reduced, now measuring only 1cm<sup>2</sup>. The pain score had also reduced to 2/10. Dressing changes could now be reduced to once weekly; the wounds continued to improve. Unfortunately, the patient was lost to follow-up, so the time to complete healing could not be determined.

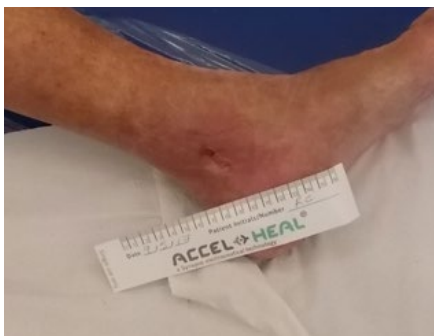
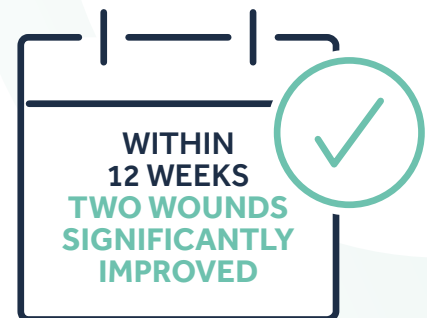
Figure 4. Left medial wound on 09/05/17

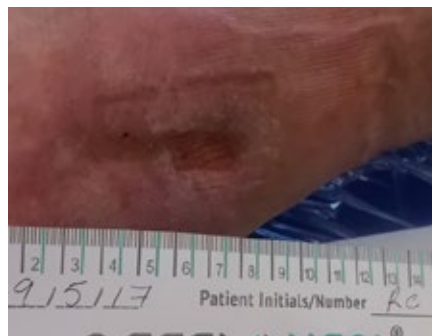


Figure 5. Right medial wound on 09/05/17

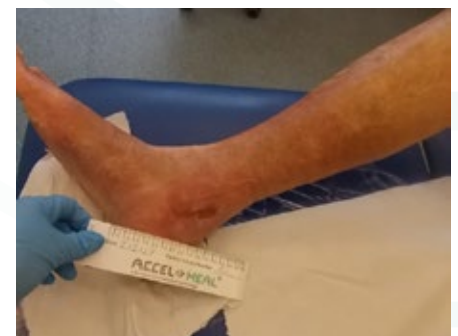

Figure 6. Right medial wound on 09/05/17



## CASE STUDY SIX

# IMPROVING DURABILITY OF HEALING IN PATIENTS WITH PREVIOUS RECURRENCE

## SUMMARY

A patient with a history of a repeatedly recurring venous leg ulcer was treated with Accel-Heal. The wound healed 13 weeks after Accel-Heal therapy.

No recurrence of this previously challenging wound was observed for at least two years after therapy.

## BEFORE ACCEL-HEAL

A 46-year-old, self-caring patient with a history of repeatedly recurring venous leg ulcers presented with a fourth recurring ulcer which had been present for several weeks. The wound had recurred despite wearing class 3 compression hosiery.

At presentation, he was suffering from depression and was unable to return to work, seeing "no future" for himself "with these recurring wounds".

The patient had suffered a past fracture to his left tibia and a left deep vein thrombosis following a road traffic accident in 1989 and was unsuitable for venous surgery.

The wound measured approximately 8cm<sup>2</sup> and was not painful.

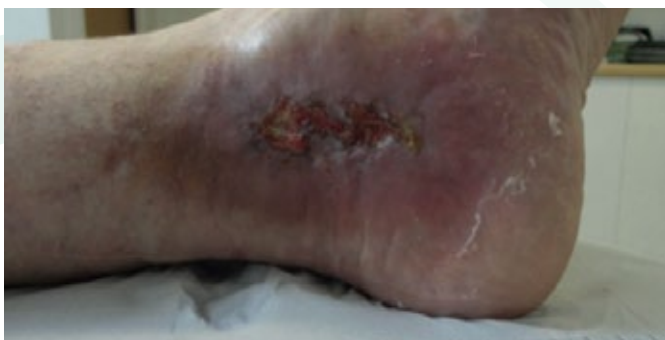

Figure 1. Medial left malleolus on 17/02/13 on start of Accel-Heal

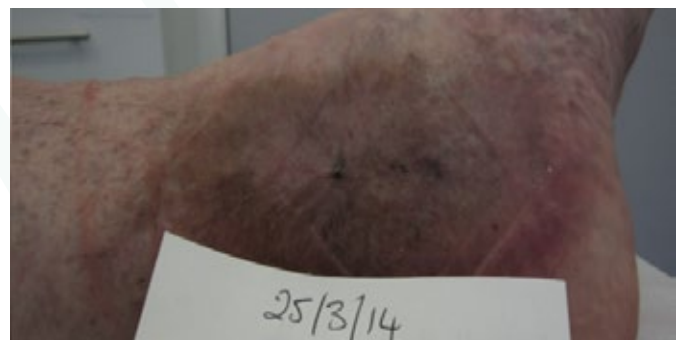

Figure 2. Medial left malleolus on 25/03/13. Wound healed

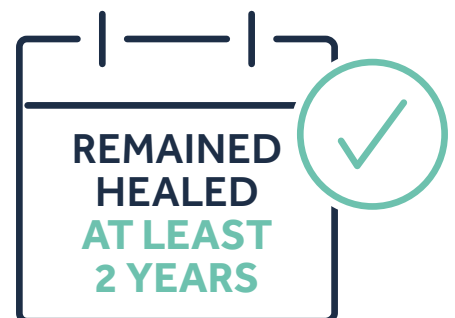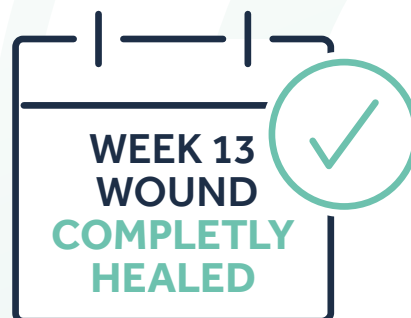## DURING THERAPY

The 12-day Accel-Heal therapy was started with a primary goal of kick-starting wound healing. A secondary goal was to improve the quality of healing to reduce the risk of future recurrence.

Along-side Accel-Heal, wounds were managed with standard moist wound healing and graduated high compression bandaging and dressings were changed twice weekly.

## AFTER THERAPY

The wound was noted to be completely healed within 13 weeks. The wound remained healed for at least two years after the Accel-Heal therapy, at which point the patient was lost to follow up.



## CASE STUDY SEVEN

## IMPROVING DURABILITY OF HEALING IN PATIENTS WITH PREVIOUS RECURRENCE

### SUMMARY

A patient with a fifth recurrence of an ulcer, whose wounds had never before remained healed for more than three months, was treated with Accel-Heal.

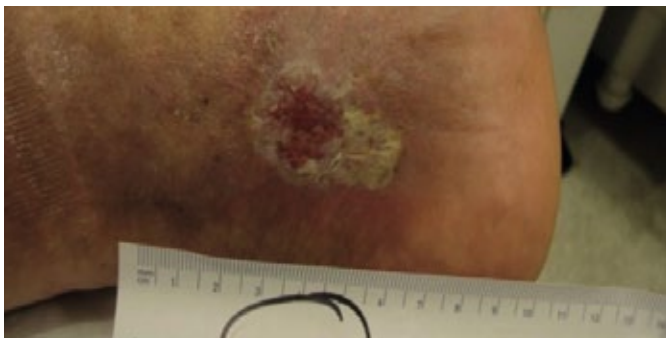The rapid wound healing observed after Accel-Heal therapy appeared more durable, with no recurrence of the wound for at least 12 months.

### BEFORE ACCEL-HEAL

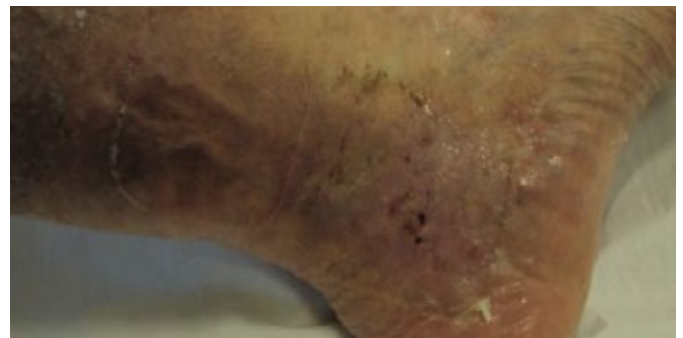
A 57-year-old patient with a history of deep vein thrombosis (DVT) and previous venous surgery presented in September with a venous leg ulcer of 4 weeks duration. This was the fifth time that this ulcer had recurred.

In the past, the patient's wound had never remained healed for longer than three months, despite his wearing class 3 compression hosiery. He stated that he "never felt the wound completely healed after each recurrence".

The wound measured approximately 7cm<sup>2</sup> and was very painful, with a pain score of 7/10.



**Figure 1. Medial left malleolus on 17/09/14 on start of Accel-Heal**



**Figure 2. Medial left malleolus on 08/10/13. Wound healed at 3 ½ weeks**

## DURING THERAPY

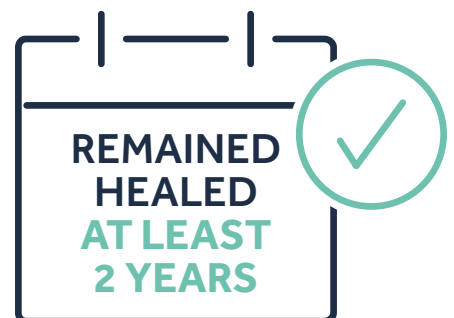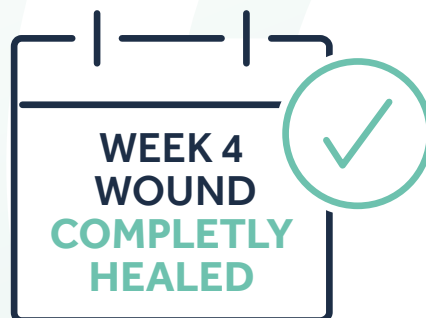The 12-day Accel-heal therapy was commenced, with the aim to reduce the pain, and kick-start healing. A secondary aim was to improve the quality of healing to reduce the risk of recurrence. Accel-Heal therapy was applied along-side standard moist wound healing and high compression bandaging.

The wound was cleansed and debrided during dressing changes. Within one week of therapy with Accel-Heal the pain had considerably reduced and the wound was clean and advancing.

## AFTER ACCEL-HEAL

The wound completely healed within 3.5 weeks of starting therapy with Accel-Heal, by mid-October.

Although the patient's wound had previously repeatedly broken down within 3 months of healing, this time there was no recurrence within 12 months at which point the patient was lost to follow up.



## CASE STUDY EIGHT

## IMPROVING PATIENT QUALITY OF LIFE

## SUMMARY

A patient with a large, malodorous and highly exudative venous leg ulcer of 15-months duration was treated with Accel-Heal.

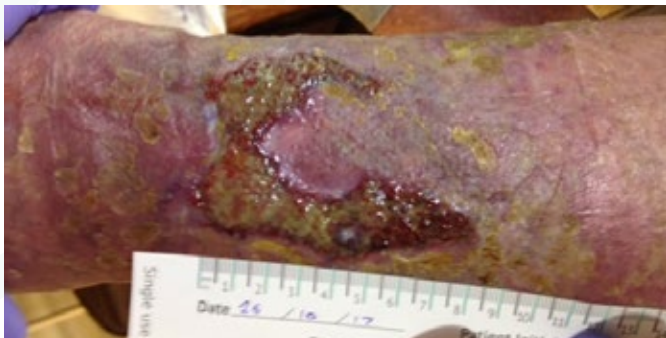Exudate and malodour reduced rapidly after therapy commenced, meaning the patient was confident to once again spend time with his family. The wound healed 12 weeks after commencing Accel-Heal therapy.

BEFORE  
ACCEL-HEAL

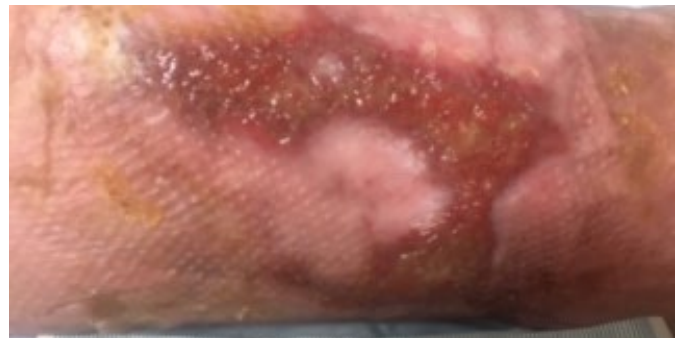
A 75-year-old patient had a 20-year history of Parkinson's disease which caused reduced mobility.

Limb assessment showed signs of venous disease and normal ankle brachial pressure index, making him a suitable candidate for graduated high compression therapy.

The patient had previously been treated with several advanced therapies and topical steroids. Despite this, the wound measured approximately 8.5cm x 6cm. Exudate was heavy and malodorous, and he was receiving four times weekly dressings. The wound was not painful.



**Figure 1. Wound to right lateral aspect on 26/10/17 prior to Accel-Heal therapy**



**Figure 2. Wound to right lateral aspect on 07/11/17 at week 2 following completion of Accel-Heal**

## DURING THERAPY

The patient agreed to Accel Heal therapy in October 2017 and continued for 12 days, while standard care continued with high compression therapy and moist wound healing as per local protocol.

## AFTER THERAPY

Two weeks after starting therapy with Accel-Heal, the wound measured 5cm x 6.5cm. Exudate had significantly reduced with no malodour and required only twice weekly dressings.

The patient was able to see his grandchild, which was previously prevented because of the malodour.

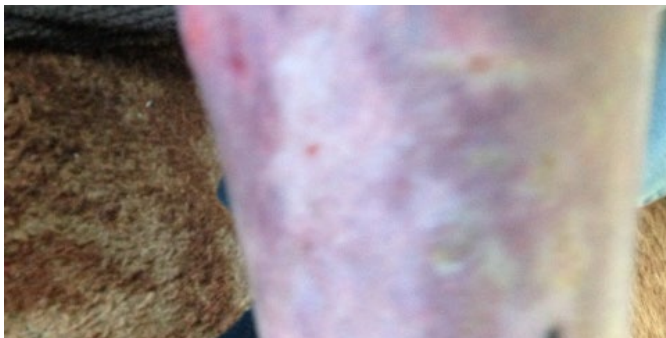

Figure 3. Wound healed at week 12



## CASE STUDY NINE

## IMPROVING PATIENT QUALITY OF LIFE

### SUMMARY

An elderly patient with a history of venous leg ulcers presented with two ulcers of 7 weeks duration.

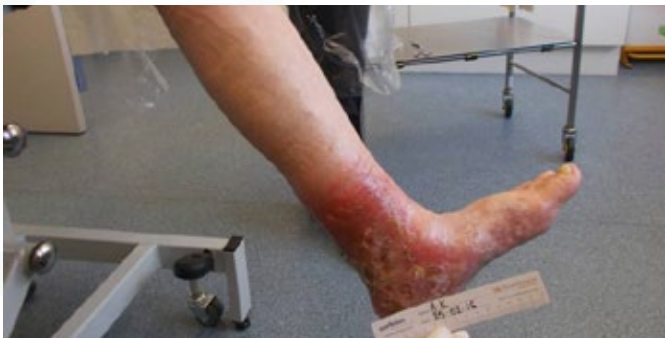One wound healed within four weeks and considerable improvement was noted to the second wound which went on to completely heal within 38-weeks following issues with varicose eczema.

### BEFORE ACCEL-HEAL

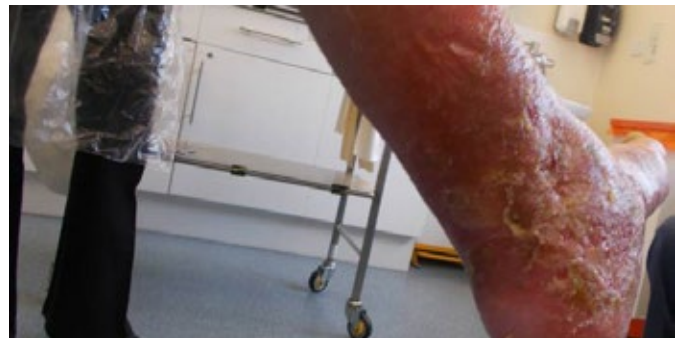An 80-year old patient with a history of venous leg ulcers in 2007 and 2012 presented with two recurring ulcers on the left inner side of the ankle, extending extensively to the back of the ankle and back of the leg. The ulcers had been present for seven weeks and had developed spontaneously, despite wearing class 2 compression hosiery. Limb assessment identified signs of venous disease.

Wound pain was scored 5/10 despite taking regular analgesia. The patient was reluctant to increase up the analgesic ladder and alternative means of relieving pain were considered.

Antibiotics had been prescribed following a positive wound swab. The wound was dressed two-to-three times weekly, with antimicrobial cleansing and debridement during dressing changes. Graduated reduced compression bandages (approximately 20 mmHg at the ankle) were used between dressing changes but high compression therapy was not tolerated.



**Figure 1. Left medial aspect 25/02/16**



**Figure 2. Left posterior aspect 25/02/16**



## DURING THERAPY

The 12-day Accel-Heal therapy started in March. The aims of therapy were to reduce the inflammation, pain and exudate and expedite healing.

Instructions were provided to the patient's wife to change the Accel-Heal device every 48-hours and the dressing regime continued three times weekly when the nursing team changed the electrode pads.

Due to the extensive size of the wounds, the two electrode pads were applied at opposite sides of the wound/s, avoiding the risk of exudate saturating the wound due to leg dependency. Standard therapy with graduated reduced compression continued during and after the Accel-Heal therapy.

## AFTER ACCEL-HEAL

During April, a great improvement was noted; exudate was decreased and the pain score reduced to 4/10 with no pain by the end of April.

One wound became infected and required two further courses of antibiotics between April and June, but the wound did not deteriorate. The patient could now tolerate graduated high compression therapy.

The patient developed marked varicose eczema and was prescribed an intensive course of topical steroids and emollients. The eczema and wounds were completely healed in December.

The patient was so delighted with the outcome he wrote a lovely letter - he could not believe the result when previous ulcers had taken so long to improve. He stated he had a huge improvement to his quality of life with no pain and no wet leaking legs.

**0/10  
PAIN  
SCORE**

**AFTER  
4 WEEKS**

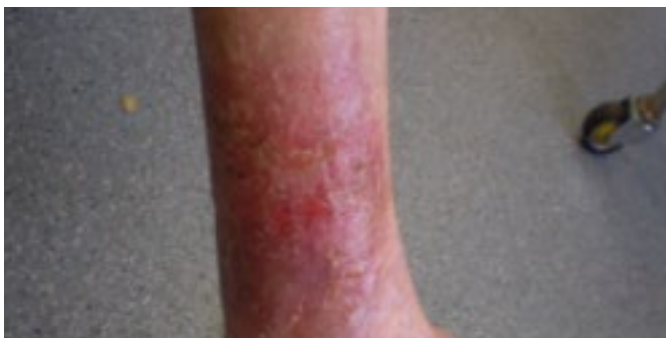

Figure 3. Left medial aspect on 07/04/16

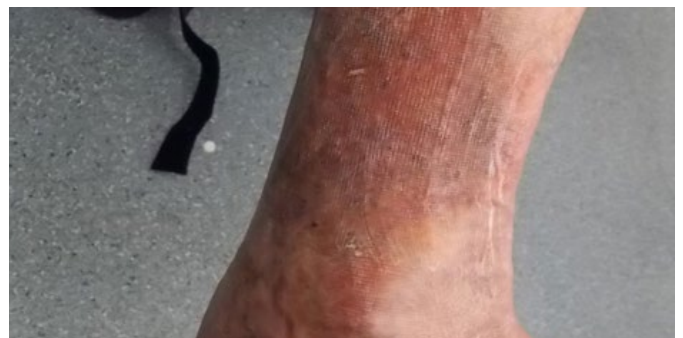

Figure 4. Left medial aspect 12/01/17. Wounds healed

## CASE STUDY TEN

## IMPROVING PATIENT QUALITY OF LIFE

### SUMMARY

A 56-year-old patient developed non-healing wounds following chicken pox. The patient became very frustrated and down about the lack of progress, his wounds having been present for 15 months. Wounds were very painful despite analgesia and antimicrobial dressing being used.

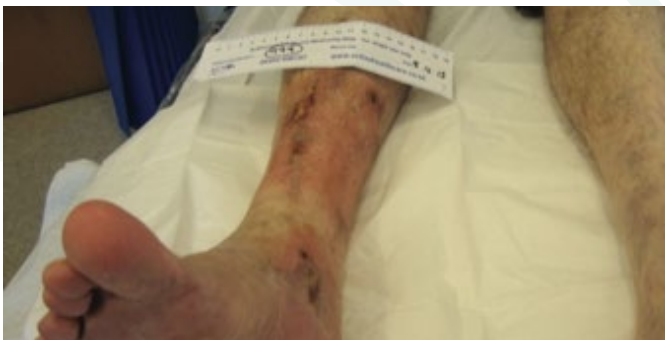Therapy with Accel-Heal relieved pain and kick-started healing; the wound was healed within five months after starting Accel-Heal therapy, improving the patient's mental health.

### BEFORE ACCEL-HEAL

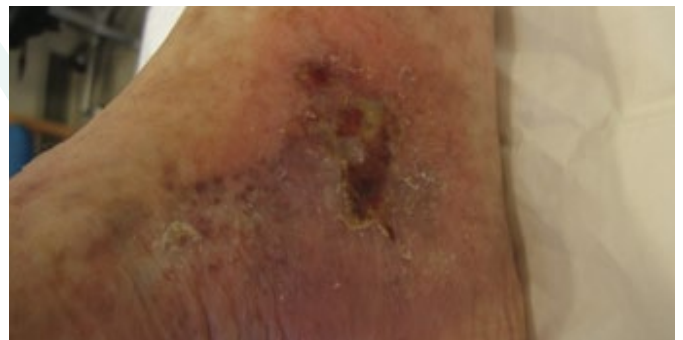
The patient, who was the main carer for his mother, developed chicken pox in August 2012. He presented in April 2013, with two wounds to his right leg, which had developed as a result of the infection. He had a past medical history of fracture of the right tibia and fibula with insertion of a plate; previous radiology had excluded osteomyelitis. Venous duplex revealed evidence of some venous incompetence but no deep vein thrombosis.

Despite being suitable for venous surgery, this was declined. The patient reported wound pain of 6/10 for which he was prescribed co-codamol. He was unable to tolerate any compression or support bandage.

Therapy commenced with topical anti-microbial cleansing solutions and dressings twice weekly. The patient would regularly attend the clinic but was often withdrawn, sometimes verbally aggressive and frustrated with the lack of progress with his wounds. He declined support for his mother, anti-depressants and referral to the pain clinic and initially declined Accel-Heal therapy for some time. The wound became regularly infected and the pain score increased to 8/10 despite antibiotics and analgesia.



**Figure 1. Right tibial crest and maleolus 08/04/13**



**Figure 2. Right maleolus on 08/04/13**

## DURING THERAPY

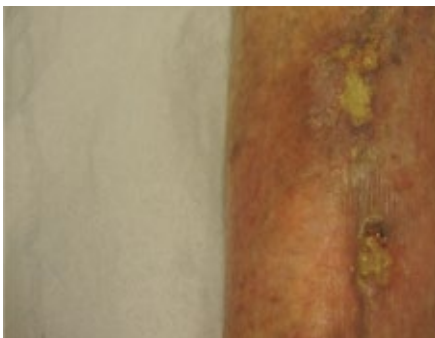
The patient agreed to try Accel-Heal therapy in November 2013 in view of non-progression, pain level and persistent infection. The electrode pads were applied to the tibial crest wounds, alongside anti-microbial dressings which were changed twice weekly during therapy.

Within one week of commencing the Accel-Heal therapy, the pain score was halved to 4/10.

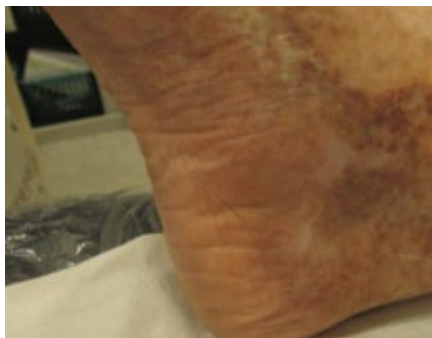## AFTER ACCEL-HEAL

By late January 2014, 2 months following therapy, there was significant improvement in the status of the wound. Pain was now reduced to 2/10.

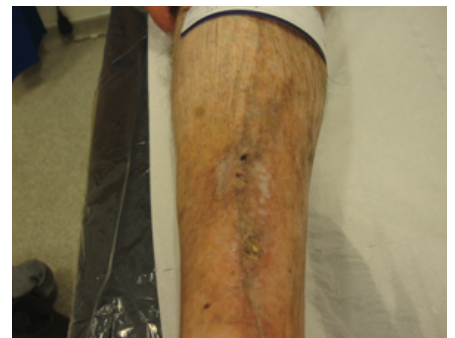The patient's mental health was noted to have improved considerably and by April, four months after Accel-Heal, all the wounds were healed. The patient was absolutely delighted with the outcome on his previously non-progressing wounds.



**Figure 3. Right tibial crest on 04/11/13 prior to commencing Accel-Heal**



**Figure 4. Right maleolus on 31/03/14 - Wound healed**



**Figure 5. Right tibial crest on 31/03/14 - wounds healed**





# Accel Heal

ELECTRICAL STIMULATION WOUND THERAPY

## REFERENCES

1. Guest J, Ayoub N, McIlwraith T et al. Health economic burden that different wound types impose on the UK's National Health Service. *Int Wound J*. 2017; 14(2):322–330.
2. Guest J, Fuller G, Vowden P. Venous leg ulcer management in clinical practice in the UK: costs and outcomes. *Int Wound J*. 2018; 15(1):29–37.
3. New research finds UK nurses carry out 180 wound dressing changes a year – on each chronic wound patient. [https://www.wounds-uk.com/news/details/new-research-finds-uk-nurses-carry-out-180-wound-dressing-changes-a-year-on-each-chronic-wound-patient-].
4. Price P, Fogh K, Glynn C et al. Managing painful chronic wounds: the Wound Pain Management Model. *Int. Wound J*. 2007. 4(Suppl 1):4-15.
5. Hellström A, Nilsson C, Nilsson A, Fagerström C. Leg ulcers in older people : a national study addressing variation in diagnosis , pain and sleep disturbance. *BMC Geriatr*. 2016:1–9.
6. Khouri C, Kotzki S, Roustit M et al. Hierarchical evaluation of electrical stimulation protocols for chronic wound healing : An effect size meta-analysis. *Wound Repair Regen*. 2017:883–891.
7. Guest J, Singh H, Rana K, Vowden P. Cost-effectiveness of an electroceutical device in treating non-healing venous leg ulcers: results of an RCT. *J. Wound Care* 2018; 27(4):230–243.
8. Prevention and Treatment of Pressure Ulcers: Quick Reference Guide. 2009. [www.epuap.org/wp-content/uploads/2010/10/Quick-Reference-Guide-DIGITAL-NPUAP-EPUAP-PPPIA-16Oct2014.pdf](http://www.epuap.org/wp-content/uploads/2010/10/Quick-Reference-Guide-DIGITAL-NPUAP-EPUAP-PPPIA-16Oct2014.pdf)
9. Piaggese A, S L, F B, Al. E. EWMA document: advanced therapies in wound management: cell and tissue based therapies, physical and bio-physical therapies smart and IT based technologies. *J Wound Care* 2018; 27 (Suppl 6):1–137.
10. Magnoni C, Rossi E, Fiorentini C et al. Electrical stimulation as adjuvant treatment for chronic leg ulcers of different aetiology: an RCT. *J. Wound Care* 2014; 22(10):525–533.
11. Santamato A, Panza F, Fortunato F et al. Effectiveness of the Frequency Rhythmic Electrical Modulation System for the Treatment of Chronic and Painful Venous Leg Ulcers in Older Adults. 2012.
12. Nair H. Microcurrent as an adjunct therapy to accelerate chronic wound healing and reduce patient pain. *J. Wound Care* 2018; 27(5):296–306.
13. Turner N, Ovens L. The results of a clinical evaluation of Accel-Heal® electroceutical treatment in a large NHS Trust. *Wounds UK* 2017; 13(4):92–99.
14. Turner N, L. Ovens. Clinical outcome results and quality of life improvements using electroceutical treatment - Patient perspectives. *EWMA* 2018, 2018.
15. L. Ovens. Supporting the Triple Aim Framework objectives in Scotland using an innovative electroceutical therapy to improve clinical and economic benefits for patients with venous leg ulcers (VLUs) Using an innovative electroceutical therapy to improve clinical. Present. *EWMA*, 2019.
16. Lynch O, Kiernan C, Strapp H et al. A study to evaluate the effectiveness of the Accel-Heal® electroceutical device as an adjunctive treatment to vascular foot ulcers. *EWMA* 2019, 2019.
17. Ovens L. Improving clinical ulcers (VLUs) using externally applied electroceutical therapy in a Community NHS Trust. Presented at Wounds UK; Harrogate, UK, November 2018.
18. Louison P, Sister S, Viability T, Study C. Management of recurrent venous leg ulcers with electroceutical therapy to improve pain , expedite healing and reduce risk of recurrence. Present. *EWMA* 2015. London, UK, 13-15th May, 2015.
19. Greaves T. Improving patient quality of life with innovative electroceutical technology: A case series. Present. *Wounds UK*, 2014. Harrogate, UK, November 2014.
20. Ovens L. Electroceutical therapy to manage complex leg ulcers: A case series of three patients. *Wounds UK*, 2014.
21. Ovens L. Getting it right for patients and budgets. *Wounds UK* 2015; 11(3):96–101.
22. N. Turner. Right Care , Right Time : - An evaluation using an electroceutical treatment to determine the clinical outcomes in a large NHS Trust.
23. Guest JF, Ayoub N, Greaves T. Clinical outcomes and cost-effectiveness of an externally applied electroceutical device in managing venous leg ulcers in clinical practice in the UK. *J. Wound Care* 2015; 24(12):574–580.
24. Martin-granados C, Mccaig CD. Harnessing the Electric Spark of Life to Cure Skin Wounds. 2014; 3(2):127–138.
25. L. Ovens. Application of Accel-Heal® for patients with chronic venous leg ulcers: an evaluation in a community UK NHS trust. *Wounds UK* 2019; 15(3):78–84.
26. Kloth LC. Electrical Stimulation Technologies for Wound Healing. *Adv Wound Care*. 2014;3(2):81-90.
27. Data on file 20191005JP

Item	Size	Product code	PIP code	NHS code
1 x Accel-Heal® therapy (6 x 48 hour units)	7cm x 4cm x 2cm	K560-6	373-0942	ELZ752

Accel-Heal  
Technologies Limited  
Hever Business Centre  
Hever, Kent, TN8 7ER

H&R Healthcare Ltd.  
3, Redcliff Road, Melton Park  
Hull HU14 3RS  
T: +44 (0)1482 631606  
E: [info@hrhealthcare.co.uk](mailto:info@hrhealthcare.co.uk)  
[www.hrhealthcare.co.uk](http://www.hrhealthcare.co.uk)

Distributed in Ireland by  
MedEarly Healthcare Ltd.  
please contact MedEarly  
Healthcare Ltd by:  
T: 087 686 4939  
E: [louise@medearly.ie](mailto:louise@medearly.ie)  
[www.medearly.ie](http://www.medearly.ie)

[www.hrhealthcare.co.uk/](http://www.hrhealthcare.co.uk/)  
**accel-heal**  
[www.accelheal.com](http://www.accelheal.com)