Accel-Heal®: a new therapy for chronic wounds

Martin Tadej, Dr Steve Young & Sylvie Hampton discuss their use of Accel-Heal®, a Class IIA medical device that proved to be particularly effective in the management of non-healing wounds

Key words:
Wound healing
Chronic wounds
Electrical charges

Chronic wounds are a challenge to any nurse and are expensive for the NHS with each chronic wound costing on average £3,000 per year and the total for all chronic wounds costing around £2 billion to £3 billion per year. The ideal result of wound healing would, of course, be rapid regeneration leading to perfect restoration of form and function (Dyson, 1997) but unfortunately this is like chasing the '*Holy Grail*' of wound healing.

Diabetic foot ulcers/sores, pressure ulcers or bed sores, venous leg ulcers and wound infections are all considered chronic wounds because their aetiologies delay and prevent healing and they persist without proper medical care (ECRI, 2009). The incidence of chronic wounds is increasing as the population ages (Edsberg *et al.*, 2002) with an estimated 200,000 people living in the UK with chronic wounds today (Posnett & Franks, 2008). With an estimated one in three community nurses aged over 50 years and one in five practice nurses over 55, this combined with the reality that the NHS is losing nurses faster than it can employ them, we cannot afford to become complacent. It stands to reason that if wounds do not heal they will require a larger workforce, which simply is not there at present and will only become further reduced with time.

Martin Tadej BA, RGN is a Tissue Viability & Research Nurse, Wound Healing Centre, Eastbourne

Dr Steve Young BSC, PhD, FRSM, Skin Science Consultancy

Sylvie Hampton MA, BSc (Hons), DpSN, RGN Work at the Wound Healing Centre, Eastbourne

Therefore, nurses should be looking to wound therapies that will increase healing potential in chronic, intractable wounds. Electrical stimulation has been shown to increase the healing potential in wounds. This product focus will review electrical stimulation in the form of a new product, Accel-Heal®. Accel-Heal® makes delivery of electrical stimulation both simple and clinically effective and the article will discuss the potential of Accel-Heal® through presenting evidence of healing in the form of case studies.

Wound healing

Wound healing is a complex process involving a sequence of biochemical and cellular events which can be divided into four distinct phases in a normal healing wound (Edsberg *et al.*, 2002). At the same time, the body has its own bioelectric system (Luther & Kloth, 2005) which influences wound healing by attracting the cells of repair, changing cell membrane permeability, enhancing cellular secretion through cell membranes and orientating cell structures as well as increasing proliferation of fibroblasts and protein synthesis.

Living tissues possess direct current surface electro-potentials that regulate, at least in part, the healing process. When a break in the skin occurs, a current termed the "*current of injury*" is generated between the skin and inner tissues that is thought to trigger biological repair (Weiss *et al.*, 1990; Sussman, 1998) and the wound begins the closely orchestrated pathway to healing. This current of injury extends up to a radius of 2–3 mm around the wound (McGinnis & Vanable, 1986; Jaffe & Vanable, 1984). To ensure that this '*healing potential*' occurs in injured skin, there is a natural epidermal battery which is located on the inside surface of the living layer of the epidermis (Barker *et al.*, 1982). After wounding, when the skin break has occurred, the epidermal battery at the wound site is short-circuited producing a conducting pathway, which allows ionic current to flow. However, when the normal wound healing process is disrupted, this "*current of injury*" is lost and the process of repair is halted and chronicity becomes inevitable (Kloth *et al.*, 1996) and the wound then can cause general debilitation of the patient and has increased potential for clinical infection. It is at this point that topical electrical stimulation can increase the potential for healing.

Electrical stimulation

As long ago as 40 years, Assimacopoulos *et al.* (1968) identified the positive effect of electrical stimulation on chronic leg ulcers that had been non-responsive to other treatment. However, this was not the earliest that this therapy had been used as electric current has been used as a therapy to treat injured tissue for centuries (Kloth, 1995). A plethora of studies demonstrate faster healing when electrical stimulation is applied (Arnold *et al.*, 1994; van Rijswijk, 1993; Rijswijk & Polansky, 1994; Robson *et al.*, 2000) and an improvement in blood flow, decrease of oedema, and an inhibited bacterial growth has been reported as well (Mohr *et al.*, 1987; Reed, 1988; Reich *et al.*, 1991; Kincaid & Lavoie, 1989).

Electrical stimulation is defined as the use of an electrical current to transfer energy to a wound (Weiss *et al.*, 1990) and this energy can help speed wound healing by increasing capillary density and perfusion, improving wound

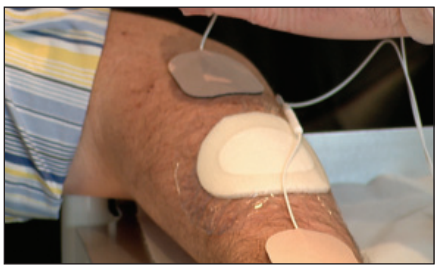

Figure 1: The electrodes. Two are positioned around the peri-wound area



Figure 2: Accel-Heal® treatment device

oxygenation and encouraging granulation and fibroblast activity (Kloth, 2002). It is also effective for enhancement of healing rates for patients with diabetes (Baker *et al*., 1997) and can be used on almost all chronic wounds including pressure ulcers, diabetic ulcers, venous ulcers and arterial ulcers. Electrical stimulation should be avoided in patients who have basal or squamous cell carcinoma in the wound or peri-wound skin, and in wounds with osteomyelitis that are not responding to systemic antibiotic therapy (Kloth, 2002).

In order to *'kick start'* the wound back into the healing process, therapeutic levels of electrical current may be delivered into the wound tissue from an external source (Kloth *et al.*, 1996). There are numerous clinical reports, including at least nine randomised controlled clinical trials, which have documented that electrical stimulation accelerates wound closure in chronic wounds including diabetic ulcers (Houghton & Campbell, 1999; Luther & Kloth, 2005; Houghton, 1999; Lundeberg, 1992; Baker *et al*., 1997; Akai *et al*., 2002). Nevertheless, acceptance of electrical stimulation for wound healing by the medical community has been a long and complex task (Sussman, 1998).

Diabetic foot and electrical stimulation

The *American College of Foot and Ankle Surgeons* clinical practice guideline for diabetic foot disorders discusses electrical stimulation as an adjunctive treatment modality for wound care (Frykberg *et al.*, 2006).

Petrofsky *et al.* (2009) found that local heat combined with electrical stimulation worked well together to heal chronic diabetic foot wounds and suggested that a warm environment was a vital part of the success of electrical stimulation, particularly in the diabetic foot.

Ischaemic ulcers

Any treatment may be of limited benefit, if an adequate blood supply to the affected area is poor, especially in severe cases such as extensive diabetic ulcers, ischaemic flaps, necrotic wounds and large areas of skin loss (Sumano *et al*., 2002).

Early studies by Wolcott *et al.* (1969) showed that ischaemic ulcers heal significantly faster with electrical stimulation and this was later supported by the findings of many other researchers (Gault & Gatens, 1976; Carley & Wainapel, 1985; Kloth & Feedar ,1988; Mulder, 1991; Griffin *et al*., 1991; Feedar *et al*., 1991).

Patients with ischaemic limbs will feel cold to the touch. These patients sometimes remark that their lower extremities feel warmer with the electrical stimulation than without it (Cukjati & Savrin, 2004).

Bacterial colonisation

All chronic wounds will be colonised with bacteria, and this does not necessarily interfere with the healing process. Therefore, it is not the presence of bacteria (Kerstein, 1996) but their interaction with the host that determines the organisms' influence on chronic wound healing. There is a significant effect of electrical stimulation on bacteria (Merriman *et al.*, 2004; Mohr *et al.*, 1988) that has been known for as long as electrical stimulation has been used (Wheeler *et al.*, 1971; Rowley *et al*., 1974; Kincaid & Lavoie, 1989). Moore (2007) identified that even the smallest electrical charge would destroy the biofilms that are common to bacteria and act as their protection against antibiotics.

Accel-Heal®

Traditionally, electrical stimulation has been difficult to apply to wounds as it requires a probe to be placed into the wound up to twice daily. This reduces patients' quality of life and uses scarce resources in the form of staff levels and clinic time. Accel-Heal® is a small class IIa medical device that once in place will deliver a specific sequence of micro-current electrical pulses to interact with innate biological processes. Accel-Heal® application involves the placement of electrodes (*Figure 1*) in close proximity to the wound. A small electrical current is then delivered through the wound and periwound tissue. Both electrodes are

High Frequency Ultrasound demonstrating healing with Accel-Heal®

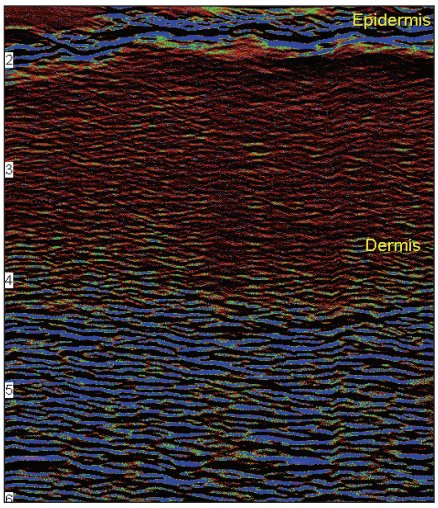

Figure 3: Day 1. Standard treatment was applied.

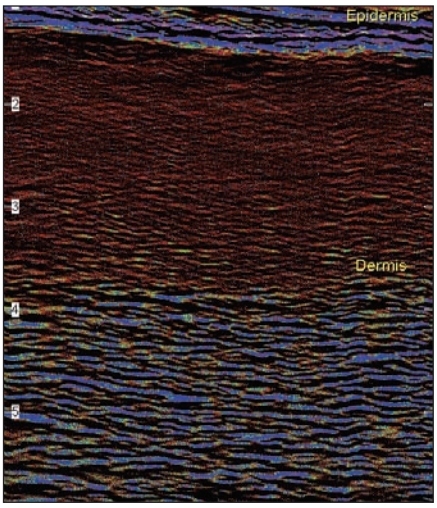

Figure 4: The HFU clearly shows that healing has not occurred in the 4 week period. Accel-Heal® was applied at this point.

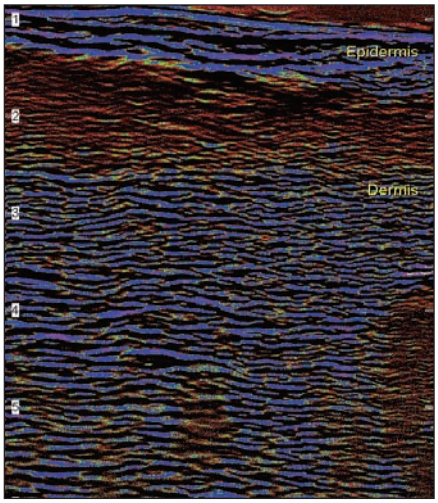

Figure 5: Healing has been rapid following application of Accel-Heal®, showing that ES does increase healing potential. Accel-Heal® was discontinued at this point.

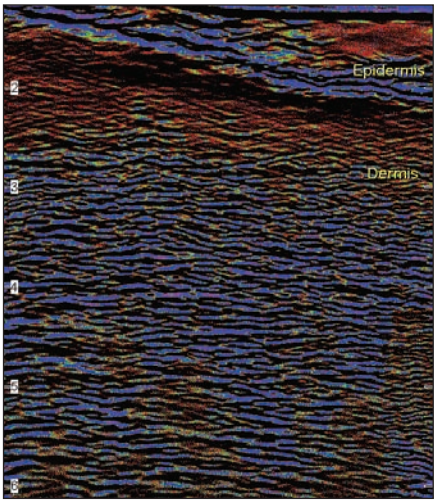

Figure 6: The discontinuation of Accel-Heal® has led to the slowing down of the healing process. This was consistently shown in all 30 wounds.

positioned on intact skin on opposite borders of the wound, straddling the lesion (Kloth, 2002).

Once in position the two leads, seen in *Figure 1*, can be connected to the small treatment device (*Figure 2*) which can be secured to the top of a stocking or bandage. The Accel-Heal® device is small and discrete and the leads can be fed through the bandage to be connected, or can emerge from the top of hosiery.

Case studies

The Wound Healing Centre undertook clinical evaluations in 30 wounds, using high frequency ultrasound (HFU) to enable analysis of healing potential when electrical stimulation was applied. The wounds were all identified as non-healing prior to commencement of the evaluation. This was demonstrated by HFU on day one, then standard treatment for four weeks (whichever dressing was being used at the time of admission to the Wound Healing Centre). At the four week point, HFU was undertaken to confirm non-healing, and the Accel-Heal® was applied for a 10 day period. If any wound had shown healing since the first visit the patient was excluded from the evaluation.

As a wound heals the natural '*current of injury*' also reduces (Jaffe & Vanable, 1984). The aim of 10 days of therapy was to '*kick-start*' healing and to mimic the natural '*current of injury*'. At the end of the 10 to 14 day period, Accel-Heal® therapy was discontinued and HFU was used to provide a scientific assessment of each wound to observe if '*kick starting*' the healing process would continue over a longer period.

Assessment of wounds has traditionally relied on the experience and knowledge of the healthcare worker who carried out the assessments and this is, at

Figure 7: The wound on admission in October 2008. Deep, painful and excoriation over the periwound area.

Figure 8: Day 1 of the evaluation. At this point, standard care was applied and Accel-Heal® not used

Figure 9: Following 4 weeks standard care, the wound is even larger. At this point, Accel-Heal® is applied.

Figure 10: After 2 weeks of Accel-Heal®, the healing is significant with large areas of epithelial tissue appearing. The pain has gone and exudate is reduced.

Figure 11: Following removal of Accel-Heal® the wound again deteriorated and therefore Accel-Heal® was reapplied with the intention of treating until healing was fully established.

Figure 12: The pads of Accel-Heal® in situ. The leads are fed through the bandages to sit on the surface. This connects to the Accel-Heal® treatment device, which then secures to the outside of the bandage.

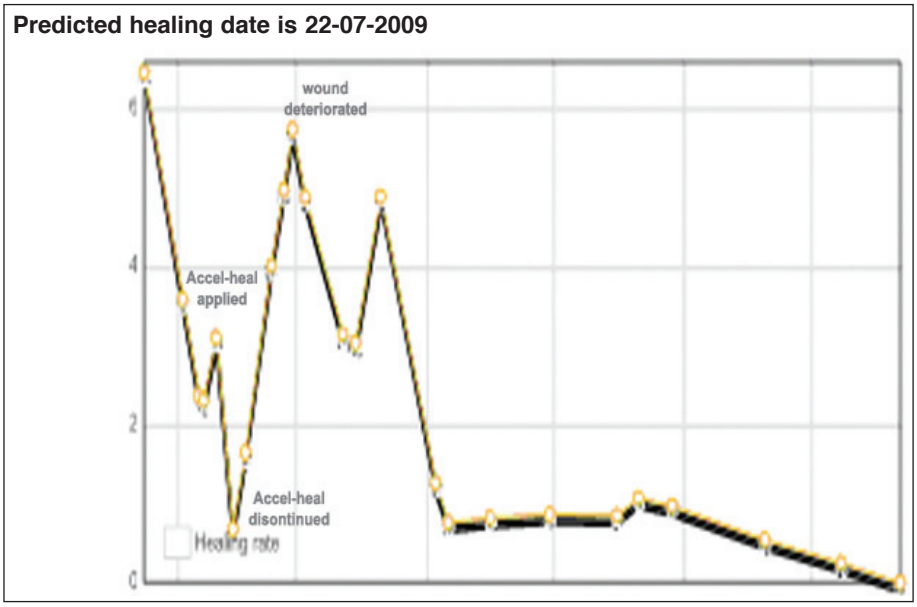

Figure 13: This graph clearly shows how Accel-Heal® stimulated the wound to heal and how the wound deteriorates when Accel-Heal® is discontinued. Once the decision was made to continue Accel-Heal® to healing, the wound made excellent progress.

best, a subjective method of assessment. The Wound Healing Centre in Eastbourne uses a system of HFU to visualise the wound surface and the tissues beneath the wound bed, thereby opening up the lower structures to examination without need for biopsy and providing accurate, verifiable and statistical data related to healing. This enables the wound healing to be quantified, giving a non-invasive and accurate method for evaluating the therapeutic efficacy of any dressing that is applied to the wound.

Figure 3 is a visual representation of the surface of the wound (blue tissue) with the unnatural oedematous tissue below the wound bed (dark red) and the natural undamaged tissue in blue striations. *Figure 3* is day one of the evaluation. Accel-Heal® was not applied at this point as standard care (whatever the patient was already using) would continue. This was to establish a baseline of non-healing status. If the wound showed signs of healing during this period, they were discontinued from the evaluation as changing the dressing would be uneccessary.

Figure 4 clearly shows that, at the fourth week, there is no healing occurring. At this point Accel-Heal® is applied and *Figure 5*, at 14 days later, very clearly shows a reduction in the oedema and an increase in healthy tissue (blue striations). At this point, Accel-Heal® is discontinued in all 30 wounds and *Figure 6* demonstrates the affect this had on the wounds as, once again, no healing has occurred during this period. This is a significant finding that was consistent in 29 out of 30 wounds.

Pain pre-commencement of electrical stimulation was an average of 5.3 on a score of 0 (no pain) to 10 (worse pain imaginable) with the potential score with 30 patients being 300. At the end of the evaluation, pain decreased to 1.6 (a reduction of 69.8 per cent).

Exudate loss was assessed on a score of 1–10, with 10 being very high loss. The assessment was undertaken by the same nurse specialist each time, in order to maintain consistency of assessment. The outcome was an average of 5.8 on commencement with a reduction to 2.8 post evaluation (51.7 per cent lower fluid loss).

One patient's outcome was particularly interesting. Mr B, a 64 year old gentleman, had a large and extremely painful ulcer on his right medial malleolus which had been in a non healing state since the day he retired, four years previously. There was excoriation around the periwound area which increased the soreness felt in the wound.

Mr B was admitted to the Wound Healing Centre in October 2008 (*Figure 7*) and the best efforts of the highly experienced nurses in the centre had a negative response in the wound. Therefore, Mr B gave his permission to be a case study using Accel-Heal®.

The protocol was followed and Accel-Heal® was applied following the second HFU scan when non-healing was confirmed (*Figure 8*).

The graph in *Figure 13* clearly shows how Accel-Heal® stimulated the wound to heal and how the wound deteriorated when Accel-Heal® was discontinued. Once the decision was made to continue Accel-Heal® to healing, the wound made excellent progress (*Figure 14*) and finally healed in July 2009 (*Figure 15*).

Conclusion

Wound healing can certainly be a challenge for the practitioner who has to dedicate treatment time on wound care and also a challenge for the NHS when £2 billion to £3 billion per year must be found for treatment of these chronic wounds.

The results of the case study (Mr B) was typical of all other case studies when

Figure 14: Wound making excellent healing progress

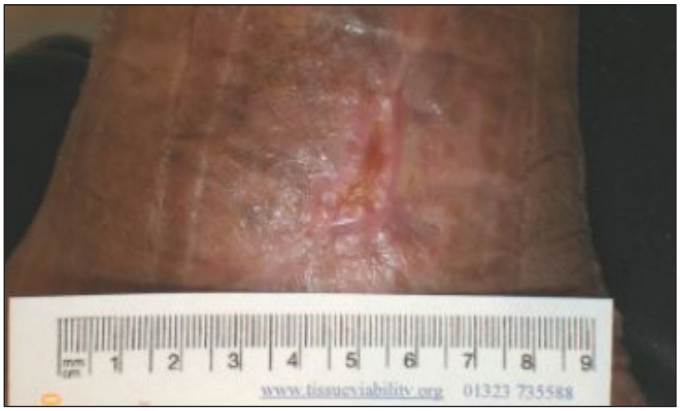

Figure 15: Wound healing complete

Accel-Heal® was applied, leading to a conclusion that wound care need not be such a challenge if electrical stimulation is used as therapy for chronic wounds. Therefore, the clinical implications of applying Accel-Heal® should be considered as overcoming or restricting the effects of lengthy or treatment-resistant wound healing may enable the practitioner to address other health issues such as the prevention of wounds.

References

Akai, M., Hayashi. K. (2002) "Effect of electrical stimulation on musculoskeletal systems: a meta-analysis of controlled clinical trials". *Bioelectromagnetics*.23;2:132-43.

Arnold, T.E., Stanley, J.C., Fellows, E.P. (1994) "Prospective, multicenter study of managing lower extremity venous ulcers". *Annals of Vascular Surgery*.8:356-362

Assimacopoulos, D. (1968) "Low intensity negative electric current in the treatment of ulcers of the leg due to chronic venous insufficiency. Preliminary report of three cases". *American Journal of Surgery.* 115;5:683–7.

Augustinsson, L.E., Carlsson, C.A., Holm, J., Jivegård, L. (1985) "Epidural electrical stimulation in severe limb ischemia. Pain relief, increased blood flow, and a possible limb-saving effect". *Annals of Surgery*, 202;1:104-10.

Baker, L.L., Chambers, R., DeMuth, S.K., Villar, F. (1997) "Effects of electrical stimulation on wound healing in patients with diabetic ulcers". *Diabetes Care* March. 20;3: 405-412

Barker, A.T., Jaffe, L.F., Vanable, J.W. (1982) "The glabrous epidermis of cavies contains a powerful battery". *American Journal of Physiology* 242;3:358–366.

Carley, P.J., Wainapel, S.F. (1985) "Electrotherapy for acceleration of wound healing: Low intensity direct current". *Archives of Physical Medicine and Rehabilitation* 66;7:443-446.

Cukjati, D., Savrin, R. (2004) "Electric current wound healing". In Rosch, P.J., Markov, M.S., *Bioelectromagnetic Medicine*, New York: Marcel Dekker

Dyson, M. (1997) "Advances in wound healing physiology: the comparative perspective". *Veterinary Dermatology*. 8: 227-233,

ECRI Institute. Hotline Response [database online]. Plymouth Meeting (PA): ECRI Institute (2009) *Jul 6. Electrical Stimulation and Electromagnetic Therapy for the Treatment of Chronic Wounds*. Available at URL address: http://www.ecri.org

Edsberg, L.E., Brogan, M.S., Jaynes, D., Fries, K. (2002) "Topical Hyperbaric Oxygen and Electrical Stimulation: Exploring Potential Synergy" *Ostomy Wound Management*, **48;**11: 42-50.

Feedar, J.A., Kloth, L.C., Gentzkow, G.D. (1991) "Chronic dermal ulcer healing enhanced with monophasic pulsed electrical stimulation". *Physical Therapy*. 71;9:639-649.

Frykberg, R.G., Armstrong, D.G., Giurini, J., Edwards, A., Kravette, M., Kravitz, S. (2000) "American College of Foot and Ankle Surgeons. Diabetic foot disorders: a clinical practice guideline", *Journal of Foot Ankle Surgery*.39;5 Suppl:S1-60.

Gault, W.R., Gatens, P.F. (1976) "Use of low intensity direct current in management of ischemic skin ulcers". *Physical Therapy*.56;3:265-269.

Griffin, J.W., Tooms, R.E., Mendius, R.A. (1991) "Efficacy of high voltage pulsed current for healing of pressure ulcers in patients with spinal cord injury". *Physical Therapy*, 71;6:433-442, discussion 442-444.

Habiba, A., Thawer, P.T., Houghton, P.E., Kloth, L.C., Butryn, A. (2000) "Effects of Electrical Stimulation on Wound Closure in Mice with Experimental Diabetes" *Mellitus Wounds*. 12;6:285–93

Houghton, P.E., Campbell, K.E. (1999) "Choosing an adjunctive therapy for the treatment of chronic wounds". *Ostomy and Wound Management*; 45;8:43-52.

Houghton, P.E. (1999) "Effects of therapeutic modalities on healing: A conservative approach to the management of chronic wounds". *Physical Therapy Review,* 4:167-82.

Jaffe, L., Vanable, J. (1984) "Electrical fields and wound healing". *Clinical Dermatoogyl.* 2;3:34–44

Kerstein, M.D. (1996) "Wound infection: Assessment and management". *Wounds* 8:141-4.

Kincaid, C.B., Lavoie, K.H. (1989) "Inhibition of bacterial growth *in vitro* following stimulation with high voltage, monophasic, pulsed current". *Physical Therapy*. 69:651-655.

Kloth, L.C. (2002) "How to use electrical stimulation for wound healing" *Nursing*, Dec 32;12:17.

Kloth, L.C., McCulloch, J.M. (1996) "Promotion of Wound Healing with Electrical Stimulation". *Advances in Skin & Wound Care* 9;5:42-45

Kloth, L.C., Feedar, J.A. (1988) "Acceleration of wound healing with high voltage, monophasic pulsed current". *Phys Ther*apy, 68;4:503-508.

Kloth, L.C. (1995) "Electrical stimulation in tissue repair" IN *Wound Healing Alternatives in Management, Second Edition.* Philadelphia: F.A. Davis Company

Kloth, L.C. (2001) "5 questions—and answers—about electrical stimulation" *Advances in Skin & Wound Care,* May/Jun 14;3:156-158

Kloth,, L.C. (2005) "Electrical Stimulation for Wound Healing: A Review of Evidence From *In Vitro* Studies, Animal Experiments, and Clinical Trials", *The International Journal of Lower Extremity Wounds*, 4;1: 23-44

Lundeberg, T.C.M., Eriksson, S.V., Malm, M. (1992) „Electrical nerve stimulation improves healing of diabetic ulcers". *Annals of Plastic Surgery*, 29;4:328-31.

McGinnis, M., Vanable, J. (1986) "Voltage gradients in newt limb stumps". *Progress in Clinical & Biological Research.* 210:231–8.

Merriman, H.L., Hegyi, C.A., Albright-Overton, C.R., Carlos, J., Putnam, R.W., Mulcare, J.A. (2004) "A comparison of four electrical stimulation types on *Staphylococcus aureus* growth *in vitro" Journal of Rehabilitation and Development* 41;2:139-146;

Mohr, T., Akers, T.M., Landry, R.L. (1987) "Effect of high voltage stimulation on edema reduction in the rat hind limb". *Physical Therapy.* 67:1703-1708

Moore, K. (2007) "Electrical stimulation for treatment of chronic wounds". *Journal of Community Nursing* 21;1: 1-6.

Mulder, G.D. (1991) "Treatment of open-skin wounds with electric stimulation". *Archives of Physical Medicine and Rehabilitation*.72;6:375-377.

Petrofsky, J.S., Lawson, D., Berk, L., Suh, H. (2009) "Enhanced healing of diabetic foot ulcers using local heat and electrical stimulation for 30 min three times per week" *Journal of Diabetes* 2;1:41-46

Posnett, J., Franks, P.J. (2008) "The burden of chronic wounds in the UK". *Nursing Times*, 104;3: 44–45.

Reed, B,V. (1988) "Effect of high voltage pulsed electrical stimulation on microvascular permeability to plasma protein: a possible mechanism in minimizing edema". *Physical Therapy*.68:491-495

Reich, J.D., Cazzaniga, A.L., Mertz, P.M. (1991) "The effect of electrical stimulation on the number of mast cells in healing wounds". *Journal of American Academy of Dermatology.* 25:40-46

Robson, M.C., Hill, D.P., Woodske, M.E., Steed, D.L. (2000) "Wound healing trajectories as predictors of effectiveness of therapeutic agents". *Archives of Surgery.* 135:773-777.

Sumano, H., Goiz, G., Clifford, V. (2002) "Use of electrical stimulation for wound healing in dogs". *Vetinary Medicine* 57;2: 31–37

Sussman, C. (1998) "Electrical stimulation" IN: Sussman, C., Byl, N, *Electrical Stimulation for Wound Healing, Wound Care Collaborative Practice Manual for Physical Therapists and Nurses*, Chapter 16, Aspen Publishers.

van Rijswijk, L. (1993) "Full-thickness leg ulcers: patient demographics and predictors of healing". *Journal of Family Practice.* 36:625-632

van Rijswijk, L., Polansky, M. (1994) "Predictors of time to healing deep pressure ulcers". *Ostomy/Wound Management.* 40:40-51;

Weiss, S.D., Kirsner, R., Eaglstein, W.H., (1990) "Electrical Stimulation and Wound Healing" *Archives of Dermatology.* 126;2:222-225.

Wheeler, C.B., Rodeheaver, G.T., Thacker, J.G. (1976) "Side-effects of high pressure irrigation". *Surgery, Gynecology and Obstetrics*. 143:775-778.

Wolcott, L.E., Wheeler, P.C., Hardwicke, H.M., Rowley, B.A. (1969) "Accelerated healing of skin ulcers by electrotherapy". *Southern Medical Journal*. 62;7: 795-801

What are your patients saying to you ?

"It caused vast improvement in the wound"

"It was comfortable to sleep with it on, it eased the pain a lot. You couldn't feel anything"

"I'm a different person, my life has changed so completely, because you know things are happening. Before nothing was happening"

"My wound is completely healed, I'm totally back to normal"

"In the first two weeks there was a massive improvement"

"You could see the improvement every week"

"It was simple and painless to use"

"You could go to bed at night and there wasn't any pain"

ACCEL HEAL™ independently clinically proven to heal hitherto non-healing venous leg ulcers.

www.accelheal.com